

Huge symptomatic pedunculated uterine fibroid in pregnancy: Antepartum myomectomy and term delivery at a specialist hospital in Kano, Nigeria

Iman Usman Haruna,¹ Jamilu Tukur,² Idris Usman Takai,² Abdullahi Mustapha Miko Mohammed,³ Ali Abdurrahman Bunawa¹

¹Department of Obstetrics and Gynaecology, Yusuf Maitama Sule University Kano, Mohammadu Abdullahi Wase Specialist Hospital, Kano; ²Department of Obstetrics and Gynaecology; ³Department of Anaesthesia, Bayero University Kano/Aminu Kano Teaching Hospital, Kano, Nigeria

Abstract

Myomas are common in pregnancy and can go unnoticed. One in ten patients, however, develops complications that would necessitate their removal. Myomectomy performed at caesarian section had come to the lime light over the last decade and recent literature have shown its safety. There is still paucity of literature on myomectomy performed during pregnancy. Our case was a 25

years old primigravida at 21 weeks with features of acute abdomen secondary to uterine fibroid which was diagnosed during pregnancy. She subsequently had antepartum myomectomy and a live birth at term via caesarean section.

Introduction

Uterine fibroids are the most common benign tumor of the uterus accounting to about 30-50% in women older than 30. They are frequently seen in the African black race of African descent.^{1,2} However, myomas are generally rare in pregnancy with a prevalence of 2% and their sizes do not increase in pregnancy.² Uterine fibroids are generally asymptomatic in pregnancy, however few patients develop complications like red degeneration and an increased frequency of spontaneous abortion, preterm labor, premature rupture of fetal membranes, antepartum hemorrhage, malpresentations, obstructed labor, caesarean section and postpartum hemorrhage.³⁻⁵ These complications may necessitate their removal. Caesarean myomectomy is cost effective having other benefits like increased chance of vaginal birth after caesarean section when removed from lower uterine segment along with decrease fibroid related complication in subsequent pregnancies.⁶ Moreover, it avoids interval myomectomy, repeat surgery and better uterine contractions in the postpartum. Studies in Nigeria⁵⁻⁷ have reported similar incidences of fibroid and their complications. Despite all this advantages one has to weigh the benefits against the increased risk of hemorrhage reported to be as high as of 10%.^{1,8} The major aim of this study is to add to the existing literature of cases of antepartum myomectomy as this appears to be the second reported caesarean myomectomy in Kano.⁷

Case Report

A 25 years old primigravida presented to our antenatal unit for routine antenatal visit on the 22/4/18 at a gestational age of 21 weeks. She had history of abdominal pain, which had been recurrent over the past 3 years and increased in intensity in the last few weeks prior to presentation. There was no history of vaginal bleeding or liquor drainage and she felt fetal movements. There was no history of vomiting or constipation, however, she noticed increased frequency of micturition. There was no dysuria or urgency. She was not a known peptic ulcer disease patient. She was not a known hypertensive or diabetic and never had a surgical intervention and no known drug allergy. On examination she was not in any obvious painful distress, she was not pale nor dehydrated and showed no demonstrable pedal edema. Her pulse rate was 84 beats per minute and blood pressure of 120/80mmhg. Abdominal exam-

Idris Usman Takai, Department of Obstetrics and Gynaecology, Bayero University Kano/Aminu Kano Teaching Hospital, Kano, Nigeria.
Tel.: +2348035994552
E-mail: takaiidris@yahoo.co.uk

Key words: Uterine fibroid, antepartum myomectomy, term delivery.

Contributions: IUH: conception, protocol development, intellectual contents; JT: conception, design, editing; IUT: manuscript writing, editing, final approval for the version for publication; AMMM: conception, drafting the article; ABB: conception, protocol development, intellectual contents.

Conflict of interest: The authors declare no conflict of interest.

Ethics approval and consent to participate: No ethical committee approval was required for this case report by the Department, because this article does not contain any studies with human participants or animals. Informed consent was obtained from the patient included in this study.

Consent for publication: The patient gave her written consent to use her personal data for the publication of this case report and any accompanying images.

Availability of data and materials: All data underlying the findings are fully available.

Received for publication: 14 August 2019.
Revision received: 27 December 2020.
Accepted for publication: 27 December 2020.

This work is licensed under a Creative Commons Attribution NonCommercial 4.0 License (CC BY-NC 4.0).

©Copyright: the Author(s), 2020

Licensee PAGEPress, Italy

Annals of African Medical Research 2020; 3:86

doi:10.4081/aamr.2020.86

ination revealed non uniformly enlarged abdomen with a symphyso-fundal height of 36 cm and an irregularly shaped mass measuring 20 by 11 cm in the fundal region, non-tender, firm and nodular and one could feel below the mass separate from the uterine size of 22 weeks. Her antenatal investigations were normal and the results were as detailed in Table 1.

Obstetric ultrasound revealed a single live fetus with a biparietal diameter of 48 mm, expected date of delivery 29th September, 2018 at gestational age of 23 weeks and multiple echogenic masses within the myometrium with the largest seen in sub serous location measuring 19 cm by 12 cm. She was assessed to be a primigravida with multiple uterine fibroids with degenerative changes. Repeat ultrasound scan 2 weeks later however revealed complex abdominal mass, presumably right ovarian cyst. Other differentials were those of uterine fibroids, right sided hydronephrosis and viable pregnancy at 23 weeks. Based on the second ultrasound scan, which revealed the possibility of a twisted ovarian cyst, she was counseled for exploratory laparotomy with possible antepartum myomectomy or oophorectomy depending on the findings. Her pre-operative investigations which included full blood count, electrolyte/urea, fasting blood sugar, were normal. Two units of whole blood were grouped and cross-matched and made available for her.

Case Management

She was admitted on the 22 /5/18, reviewed by anesthetics and planned for exploratory laparotomy the next day. Consent was signed. On 23/5/2018 the patient was taken to the theatre and general anesthesia was given. The patient was cleaned and draped. A midline sub-umbilical incision was made and extended above the umbilicus. The abdomen was entered through the skin, sub-cuta-

neous tissue, up to the rectus sheath, where a longitudinal incision was made and extended using scissors to expose the rectus muscle, which was sheared laterally using blunt dissection to expose the parietal peritoneum. The parietal peritoneum was picked with 2 artery forceps and a small nip was made to expose the peritoneal cavity and the following findings noted: clean abdomino-pelvic cavity, bulky uterus about 20 weeks with a large fundally placed pedunculated sub serous fibroid measuring 20 cm by 15 cm, with a thick stalk of about 4 cm, and 2 cm away from the uterine wall. Two other intramural fibroids were also noted measuring 7 cm by 8 cm on the cervix extending to the lower segment and the other one 6 cm by 7 cm more centrally located figures (Figures 1 and 2). Grossly normal tubes and ovaries and estimated blood loss of 300 mL were observed. She had antepartum myomectomy of fundally placed fibroid measuring 20 cm by 15 cm. Hemostasis was secured and the abdomen cleaned and was closed in layers. Specimen was sent for histological examination. Histology reports revealed uterine fibroids with fatty degenerative changes.

Table 1. Antenatal investigation results.

INVESTIGATIONS	RESULTS
Packed cell volume	34%
Retroviral screening	Non-reactive
Hepatitis b surface antigen	Non-reactive
Veneral disease research laboratory	Non-reactive
Urinalysis	Normal
Blood group	0 positive

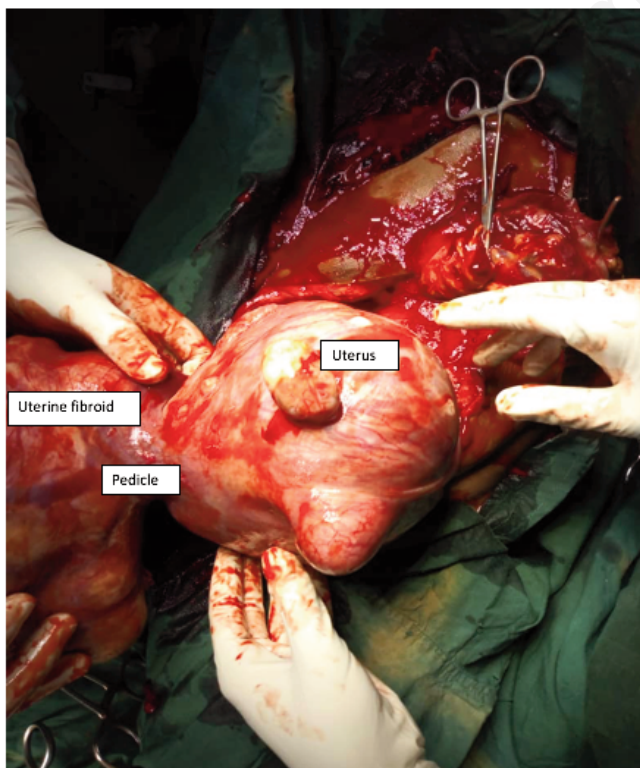


Figure 1. The huge pedunculated fibroid covered with omentum.

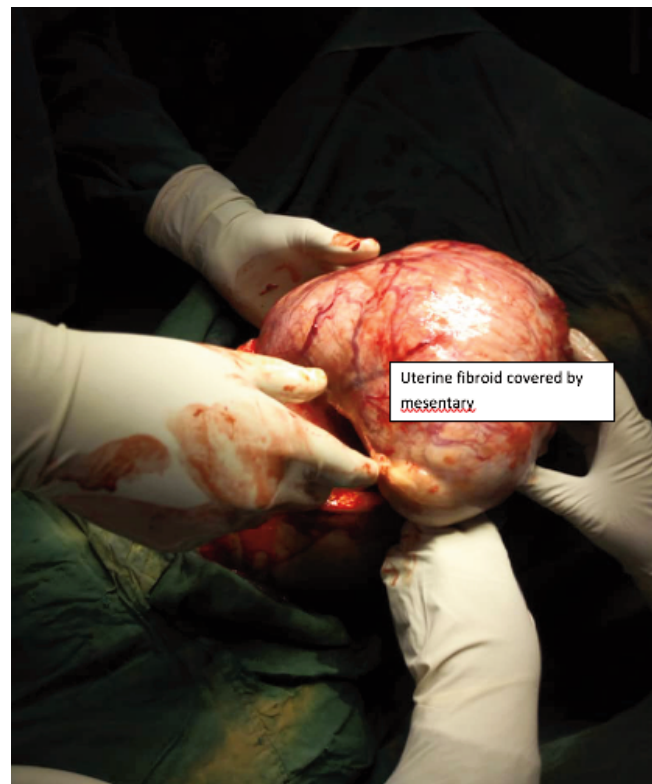

Figure 2. Pedunculated subserous fibroids covered with omentum.

Post-operative care

Post operatively she was placed on intravenous antibiotics and analgesics with intravenous fluids for 48 hours. She was also placed on nifedipine for tocolysis for one week. She was converted to oral medication after 48 hours. The patient had an episode of vaginal bleeding that lasted only 2 hours post operatively otherwise remained stable. She was discharged 7 days later and had an obstetric scan, which showed single viable pregnancy at 24 weeks and a packed cell volume of 29%. She was subsequently reviewed 2 weekly and in view of cervical fibroid she was counseled for elective Caesarian section at gestational week of 38 weeks.

Elective caesarean section

At term, she was readmitted on 13/9/18, reviewed by anesthetic team, and her pre-operative investigations which included full blood count, electrolyte/urea, fasting blood sugar, were normal. Two units of whole blood were grouped and cross-matched and made available for her. She had elective caesarian section on the 14/9/18 with delivery of live female baby weighing 2.5 kg. Apgar scores of 8 and 9 in the first and fifth minute respectively, grossly normal tubes and ovaries were observed. There was cervical fibroid 5 cm by 6 cm and smaller intramural fibroids noted. The estimated blood loss was 400 mls. Post operatively she was maintained on 20 IU of oxytocin over 4 hours and 3 tablets of misoprostol inserted per rectum to maintain a well contracted uterus. She was also placed on intravenous fluids, analgesics, haematinics and antibiotics. Her postoperative packed cell volume was 28%. She was discharged on the 7th day post-operative. She was reviewed 2 weeks later at the postnatal clinic. She had no complains with satisfactory findings on physical examination. Breast feeding was successfully established. She was reviewed 4 weeks later and was counseled for myomectomy before her next pregnancy. She was also counseled on family planning and Pap smear.

Discussion

Our patient was a 25 years old primigravida still within the age range of fibroids and had huge sub-serous symptomatic fibroids with a thick short pedunculated stalk. She underwent antepartum myomectomy, and had an uneventful postoperative period. This has shown that operating a woman with symptomatic fibroid in pregnancy could prevent complications like preterm labour, abortions, PROM and antepartum hemorrhage paving way for salvaging pregnancy and improved maternal and fetal outcome. Antepartum myomectomy is a safe procedure in selected patients and studies in West Africa had shown safety particularly for sub serous pedunculated fibroids.^{6,7} Although previous Studies had shown antepartum myomectomy contraindicated, a study by shafiee⁸ had shown removal of intramural fibroid in pregnancy is safe but not without risk if selected criterion was followed. Studies have shown increased risk of hemorrhage necessitating blood transfusion and hysterectomy.⁹ Our patient had post-operative packed cell volume of 29% which was managed conservatively. Almost all the patients were subsequently delivered via caesarian section,¹⁰ which was the same with our patient. Jhalta *et al.*¹¹ recommended that myomectomy in pregnancy should be confined to symptomatic myomas which are pedunculated with a stalk of 5 cm diameter or less and it can be done even very early in pregnancy. Selection of cases for myomectomy is critical as this reduces blood loss, anaemia and other complications.¹² Although most cases

were delivered via caesarean section a report by Adeyemi discussed a case which had vaginal delivery.¹³ During surgery we found the stalk of the myoma was about 4 cm thick and 2 cm away from the uterus. Enucleating the fibroid is technically easier in gravid uterus due to extra looseness of the capsule and dissection becomes easier.¹⁴ Complications like red degeneration and intestinal obstruction were seen in some cases and it necessitated removal.¹⁵⁻¹⁷ Sometimes myomectomy has to be performed at caesarean section where one is faced with anterior wall myomas impeding fetal extraction¹⁸ which is different from our case. Both antepartum and caesarean myomectomy can be considered a safe option with minimal or no further risk of recurrence of myomas.¹⁸⁻²⁰ There are still challenges when it comes to antepartum myomectomy since it depends on site and placental location.^{21,22} In some cases myomectomy and removal of fetus through the same incision.^{23,24} Some have tried laparoscopic myomectomy with success.²⁵ In our case we were able to remove the fundally placed fibroids and unable to remove the cervical fibroids due to risk of hemorrhage and rupture of membranes. Extensive research needs to be ongoing to consider removal of such fibroids with minimal risk. Our patient had her routine ANC care and was subsequently delivered via CS with good fetomaternal outcome. In conclusion, Obstetricians should weigh the risk and benefit of conducting an antepartum myomectomy. Generally, the risks do not favor offering the procedure for all patients with uterine fibroid in pregnancy. However, there may be reasons to offer antepartum myomectomy in certain patient such as ours with intractable abdominal pain and the risk of the patient going into preterm labour if the intervention is not offered.

References

1. Kwawukume EY. Caesarian myomectomy. Afr J Reprod Health 2003;7:125.
2. Alysha N, Patrick K, David S. Successful Antepartum myomectomy of a large pedunculated fibroid. J Gynecol Surg 2019;35:6
3. Milazzo GN, Catalano A, Badia V, et al. Myoma and myomectomy: Poor evidence concern in pregnancy. J Obstet Gynaecol Res 2017;43:1789-803.
4. Brown D, Fletcher HM, Myrie MO, Reid M. Cesarean myomectomy-a safe procedure. A retrospective case controlled study. Obstet Gynecol 1999;19:139-140.
5. Ikedife D. Surgical challenge of myomectomy at cesarean section. Nigerian J Surg Sci 1993;3:15-7.
6. Ehigiegba AE, Ande AB, Ojobo SI. Myomectomy during caesarean section. Int J Gynaecol Obstet 2001;75:21-5.
7. Omole-Ohonsi A, Ashimi AO. Caesarean myomectomy in Kano, Northern Nigeria. Ibom Med J 2016;3:45-9
8. Shafiee MN, Nor Azlin MI, Arifuddin D. A Successful Antenatal Myomectomy. Malays Fam Physician 2012;7:42-5.
9. Zaima A, Ash A. Fibroid in pregnancy: characteristics, complications and management. Postgrad Med J 2011;87:819-28.
10. Isabui J, Okogbo F, Okunsanya S, Eifediyi R. Myomectomy during early pregnancy. Mil Med 2000;165:162-4.
11. Jhalta P, Negi SG, Sharma V. Successful myomectomy in early pregnancy for a large asymptomatic uterine myoma: case report. Pan Afr Med J 2016;24:228.
12. Adesiyun AG, Ameh AC, Ojabo A. Myomectomy at Caesarean Section: descriptive study of clinical outcome in tropical setting. J Ayub Med Coll Abbottabad 2009;21:7-9.

13. Adeyemi AS, Akinola SE, Isawumi AI. Antepartum myomectomy with a live term delivery: a case report. *Nig J Clin Pract* 2007;10:346-8.
14. Sabita S, Sunita S. Antepartum myomectomy: a possible procedure for successful outcome. *Int J Reprod Contr Obst Gynecol* 2014;3:6.
15. Hayder A. Successful Myomectomy during Pregnancy for a Large Uterine Fibroid Causing Intestinal Obstruction: Report of a Case. *J Young Pharmacists* 2015;7:4.
16. Karan S, Djavid I. Fibroids in pregnancy: Management and outcomes. 2018;20:3.
17. Malani K, Jagtap S, Swaminathan G, Samant P. Caesarean Myomectomy. *J Post Grad Gynaecol Obstet* 2017;5:6.
18. Sparić R, Kadija S, Stefanović A, et al. Cesarean myomectomy in modern obstetrics: More light and fewer shadows. *J Obstet Gynaecol Res* 2017;43:798-804.
19. Bhave N, Shah P, Chaudhari H. An unusual presentation of Degenerating Fibroid. *Int J Reprod Contracept Obstet Gynecol* 2016;5:582-4.
20. Akkurt Y, Yavuz A, Yalcin SE, et al. Can we consider caesarean myomectomy as a safe procedure without long-term outcome? *J Matern Neonatal Med* 2017;30:1855-60.
21. Kamal P, Bala R, Nagpal M, Kaur H. Caesarean myomectomy: Practical issues. *Indian Jo Obstet Gynecol Res* 2017;4:249-53.
22. Awoleke JO. Myomectomy during Caesarean Birth in Fibroid-Endemic, Low-Resource Settings. *Obstet Gynecol Int* 2013;2013:20-8.
23. Chisara U, Paul F. Successful myomectomy during pregnancy: A case report. *Reproductive Health* 2005;5:7-8
24. Rekha S, Munna L, Pushpalata S. Inevitable caesarean myomectomy and removal of fetus through same incision. *Ann Tropical Med Public Health* 2016;3:4-5.
25. Fanfani F, Rossitto C, Fagotti A, et al. Laparoscopic myomectomy at 25 weeks of pregnancy: case report. *J Minim Invasive Gynecol* 2011;17:91-3.

Non-commercial use only