

# Inadvertent caustic ingestion in children in a tertiary health facility in Enugu: critical review of three cases and current literature

Ajiroghene L. Eke,<sup>1</sup> Obianuju O. Igbokwe,<sup>2</sup> Uzoamaka B. Oguchi,<sup>2</sup> Christopher B. Eke,<sup>2</sup> Kenneth Dabaerechi Adiele<sup>2</sup>

<sup>1</sup>Department of Medical Biochemistry, Faculty of Basic Medical Sciences, University of Nigeria, Enugu Campus, Enugu;

<sup>2</sup>Department of Paediatrics, College of Medicine, University of Nigeria/University of Nigeria Teaching Hospital, Enugu, Nigeria

## Abstract

Inadvertent ingestion of corrosive substances occurs frequently in children, especially in the younger age group. This could be attributed to their immaturity and the developmental stage of motor and sensory skills. The most common corrosive agent in our environment is caustic soda, which is used in soap making. This substance is usually stored in unlabelled containers without child-proof safety caps. Adequate health education and effective legislation on the production, handling, and storage of corrosive substances will help mitigate the dangers of accidental ingestion in children. We present a report of three cases of unintentional caustic ingestion among children seen in Enugu and discuss the relevant literature.

Correspondence: Ajiroghene L. Eke, Department of Medical Biochemistry, Faculty of Basic Medical Sciences, University of Nigeria, Enugu Campus, Enugu, Nigeria.  
E-mail: ekeajiroghene@gmail.com

Key words: inadvertent caustic ingestion, endoscopy, children.

Contributions: all the authors made a substantive intellectual contribution. All the authors have read and approved the final version of the manuscript and agreed to be held accountable for all aspects of the work.

Conflict of interest: the authors declare no potential conflict of interest.

Funding: none.

Availability of data and materials: all data generated or analyzed during this study are included in this published article.

Received: 22 September 2022.

Accepted: 24 November 2022.

This work is licensed under a Creative Commons Attribution NonCommercial 4.0 License (CC BY-NC 4.0).

©Copyright: the Author(s), 2023

Licensee PAGEPress, Italy

Annals of Clinical and Biomedical Research 2023; 4:239

doi:10.4081/acbr.2023.239

*Publisher's note: all claims expressed in this article are solely those of the authors and do not necessarily represent those of their affiliated organizations, or those of the publisher, the editors and the reviewers. Any product that may be evaluated in this article or claim that may be made by its manufacturer is not guaranteed or endorsed by the publisher.*

## Introduction

Accidental caustic ingestion by children is a potential indication for emergency department visits. The clinical spectrum varies from an absence of mucosal injury to complications such as severe esophageal burns or strictures, which can lead to esophageal replacement.<sup>1</sup>

Caustic ingestion affects about 5 per 100,000 people per year, mainly in developed countries.<sup>2</sup> However, the actual burden in developing countries like ours is not known due to the paucity of data. According to the recent Annual Report of the American Association of Poison Control Centers (AAPCC), about 2,334,004 human exposures occurred in the year 2011, with children five years and younger accounting for 49% of the cases.<sup>3</sup>

Commonly ingested substances in pediatric age groups, as reported from the United States, included cosmetic/personal care products (14%), analgesics (9.9%), and household cleaning substances (9.2%).<sup>4</sup>

Incidence is more common in boys under 12 years of age and in teenage girls older than 13 years, with most of these unintentional ingestions occurring at home and in nearby areas. Also, some medical conditions which have been found to increase the risk of ingestion of caustic substances and foreign bodies include: attention-deficit hyperactivity disorder, low level of parental education, young motherhood, lack of parental supervision, and residence in rural areas.<sup>4,5</sup>

In addition, curiosity, exploration of the developing oral phase, child's inexperience, and limited understanding of the environment are all the factors that expose younger children to the highest risk of ingesting foreign bodies and caustic substances with peak age at 3 years of age.<sup>1,6</sup>

The typical finding is that in children, most of the cases of ingestions are unintentional in nature, while in adults, suicidal attempts have been perfected through intentional ingestion of corrosive substances.

The driving forces for unintentional caustic ingestion in most rural and semi-urban communities of Nigeria appear to stem from a variety of factors related to caustic soda (sodium hydroxide, NaOH), which is usually sold in open markets in secondary unlabelled containers and used for household soap making, without restrictive legislation.

Usually, ingestion of a strong alkali/acid, oxidizing agent, or mixtures of these will cause chemical burns in 20-40% of children, and the injury largely depends on the chemical concentration, pH, and volume,<sup>3,7</sup> tissue surface area, duration of exposure, and the ingested form of the agent (probably in liquid, gel or solid state).

Esophageal stricture formation occurs following submucosal penetration of the burn involving more than 50% of the lumen.<sup>8</sup>

Generally, acidic ingestion produces tissue injury through coagulation necrosis, while alkali produces liquefactive necrosis and saponification, resulting in increased depth of tissue injury.

Alkali ingestion also results in thrombosis of blood vessels, which could impede blood flow, with resultant free radical damage, as well as lipid peroxidation, causing esophageal injury. Injury most typically involves the esophagus. However, gastric injury may also occur. In Nigeria, Ogunleye *et al.*<sup>9</sup> reported 23 cases over a ten-year period; other studies were done by Adegboye *et al.*,<sup>10</sup> and Ekpe *et al.*,<sup>11</sup> who observed 16 cases over a four-year period in Calabar, South-south Nigeria, among others. Unintentional corrosive ingestion and its complications, particularly corrosive esophageal stricture, can be challenging in its management in our setting. In addition, there are no clear laws and implementation of protective legislation on the handling of these corrosive substances by manufacturers and the public at the different levels of the value chain in Nigeria.<sup>12</sup> Hence, this case series will help to highlight the clinical cases seen in our practice and the available treatments, and also use the gaps in history to make a case for government agencies, like the National Agency for Food and Drug Administration (NAFDAC) and the Standard Organization of Nigeria (SON), to rise up to the occasion and enact and promulgate laws to address these preventable health challenges. This case series aims to present the cases seen in our practice, highlighting the risk factors with available treatment options, and reviewing the available literature, as well as making necessary recommendations aimed at mitigating the challenges.

## Case Reports

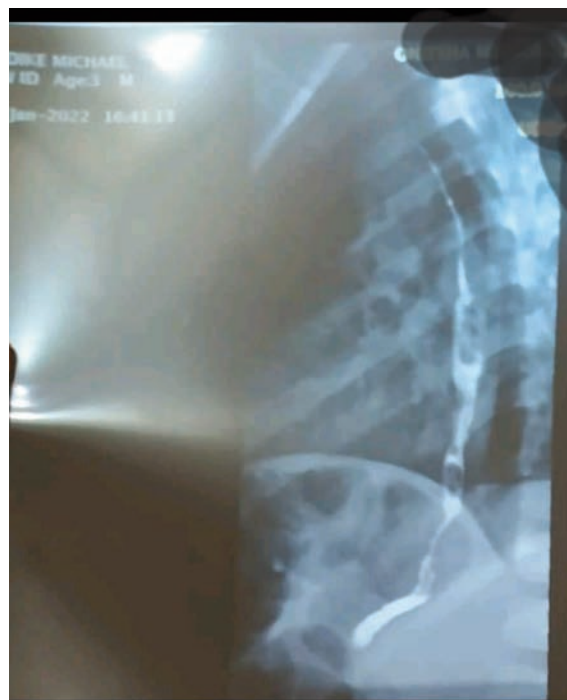### Case #1

O.C. is a 3-year-old male who lives with his parents in Enugu Urban. He presented with difficulty in swallowing for 3 weeks duration. This occurred following the ingestion of a cleaning agent (nitrocellulose) stored in a plastic container, which he mistook for water. He subsequently developed mouth ulcers and drooling of saliva. He was then rushed to a private hospital where gastric lavage was done and spent 10 days on admission. A day after discharge, he started having difficulty swallowing solid foods, and this then progressed to involve liquid and semi-solid food. Both parents are small-scale traders with secondary education. They live in a two-room apartment. However, they were visiting a family member in a newly constructed building when the incident occurred. He was subsequently referred to the University of Nigeria Teaching Hospital, Enugu, for expert care. On admission, he was conscious and appeared clinically stable. Systemic examination was not revealing, except for reduced muscle bulk. A barium swallow study revealed a long segment narrowing with multiple oval filling defects, while gastroscopy later confirmed the esophageal stricture (Figure 1). A diagnosis of esophageal stricture secondary to ingestion of a corrosive substance was made. He was reviewed by the cardiothoracic surgeons, and booked for rigid esophagoscopy and dilatation, with or without feeding gastrostomy. Intraoperatively, an attempt at rigid esophagoscopy with dilatation failed; Stamm's feeding gastrostomy was done under general anesthesia, the procedure was well tolerated, and the immediate post-operative condition was satisfactory. Currently, the child is feeding through the gastrostomy tube, and the definitive surgery is being planned.

### Case #2

E.O., a 3-year-old female, presented with a 17-day history of difficulty in swallowing, painful swallowing, drooling of saliva,

and refusal to feed. She was said to have mistakenly ingested caustic soda, which led to pain and ulcers in her mouth. She is the first child in a monogamous family of two children. Mother is a 27-year-old petty trader with a primary education, father is a 32-year-old tricycle driver with a primary education. They reside in the Igbo-Eze Local Government Area of Enugu State, Southeast Nigeria, in a two-bedroom apartment with the grandmother, who makes soap on a small scale. The caustic soda was stored in a plastic bucket with a non-locking lid, the same type of container they use for storing drinking water for the household, and this led to the accidental ingestion. For this, she was given coconut oil and palm oil to counter the effect of the caustic soda. She also received some over the counter medications, with no relief from her symptoms. Two weeks into the illness, she started having difficulty in swallowing, initially to solid foods which progressed to semi-solids, and liquids. Due to painful and difficult swallowing, she started refusing oral feeds, necessitating her presentation to the Paediatric Emergency Department of the University of Nigeria Teaching Hospital, Ituku/Ozalla, Enugu. On examination, the child was conscious, and in no obvious distress, with a pool of saliva in the mouth, no oral ulcers, the abdomen fully moved with respiration, and no organomegaly. The respiratory and cardiovascular systems examination were not revealing. Barium swallow showed an oesophageal stricture, distal to the cervicothoracic junction, with overall features consistent with a corrosive esophageal stricture (Figures 2 and 3). Hence, a diagnosis of esophageal stricture secondary to caustic soda ingestion was entertained. Cardiothoracic surgeons reviewed the child, and a feeding gastrostomy procedure was done under general anesthesia, which was well tolerated. The child is currently feeding through the gastrostomy tube.



**Figure 1.** Barium swallow showing a long-segment esophageal narrowing (stricture), with multiple oval filling defects.

### Case #3

U.C. is a 33-month-old female who presented with an hour history of breathlessness and swelling of the lips and tongue following ingestion of a poly-vinyl chloride adhesive (dichloromethane), after which palm oil was given and vomiting induced. She was then taken to a patent medicine store, where she was given intravenous hydrocortisone before being referred to the Paediatric Emergency Department of UNTH. She is the only child of her parents. The father is a carpenter with a primary education, and the mother is a housewife with a primary education. At presentation, she was conscious, with labored breathing, secretions in the mouth, and swollen lips and tongue with widespread crepitations (Figure 4). An admitting diagnosis of aspiration pneumonitis secondary to dichloromethane poisoning was made. She was commenced to intravenous ceftriaxone, dexamethasone, and intravenous maintenance fluid. CTU and anesthesiologists were invited to review her. She was then transferred to the pediatric intensive care unit and was intubated and ventilated. Available investigation results (done after intubation) included Arterial Blood Gas (ABG), which showed compensated metabolic acidosis (pH: 7.373,  $PCO_2$ : 31.5 mmHg,  $HCO_3$ : 18.3 mmol/l); serum electrolytes were essentially normal, except for hypocalcemia of 0.94 mmol/l. Chest x-ray showed bilateral homogeneous opacities, and Hemoglobin (Hb) was 10.9 g/dL. On the third day of admission, the child passed melena stool. A repeat hemoglobin level was done after about 24 hours, showing a reduction from 10 to 7 g/dL. On further examination, the child was unconscious (probably under sedation), tachypneic, tachycardiac with gallop rhythm, and presented hepatomegaly of 4 cm below the right costal margin. An additional diagnosis of anemic heart failure secondary to upper gastrointestinal bleeding was made. The child was transfused with sedimented red cells, and also commenced on intravenous ranitidine. A repeat chest x-ray done 9 days into admission showed pneumothorax, for which bilateral chest tube thoracostomy was done. On the 10<sup>th</sup> day of admission, the child was noted to have extubated herself, and as she was being re-intubated, she stopped breathing. Cardio-pulmonary resuscitation was commenced, but proved abortive, and she was certified dead subsequently.

### Discussion

In this series, we have described three important cases of caustic ingestion managed in our practice (Tables 1 and 2). It is important to note that the three cases occurred in children 3 years and

**Table 1.** Haematologic results of cases.

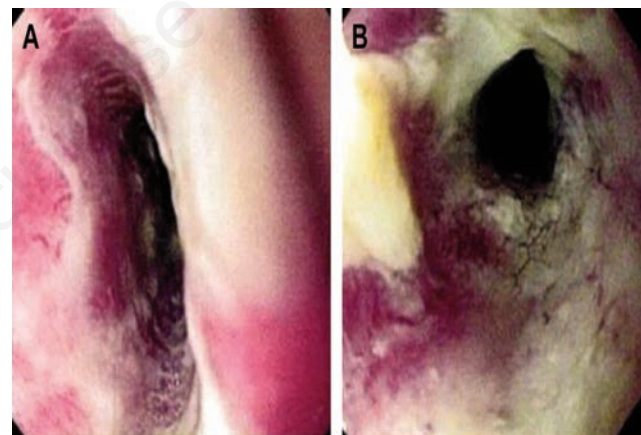
Analytes	Case #1	Case #2	Case #3
Full blood count			
Total white blood cells	$13 \times 10^9/L$	$8.8 \times 10^9/L$	$9.0 \times 10^9/L$
Neutrophil percentage	40%	48%	60%
Absolute neutrophil count	$6 \times 10^9/L$	$4.3 \times 10^9/L$	$4.6 \times 10^9/L$
Hemoglobin (Hb)	12.8g/dL	9.2g/dL	10.6g/dL
Platelets	$656 \times 10^9/L$	$284 \times 10^9/L$	$250 \times 10^9/L$

**Table 2.** Haematologic results of cases.

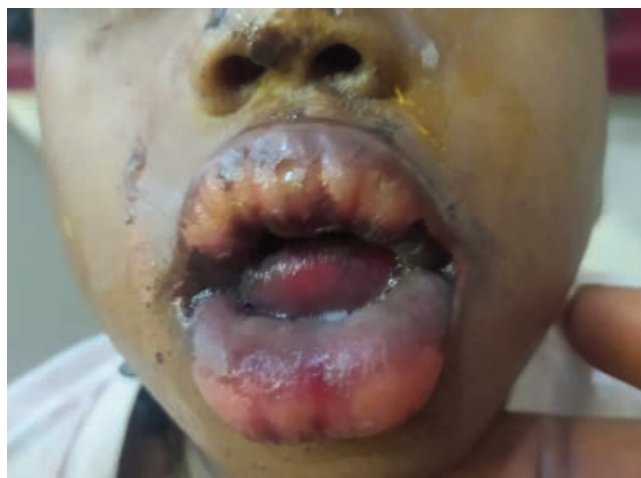Analytes	Case #1	Case #2	Case #3
Serum electrolytes, urea and creatinine			
Sodium ( $Na^+$ ) (mmol/l)	136	140	143
Potassium ( $K^+$ ) (mmol/l)	3.85	3.31	4.0
Calcium ( $Ca^{2+}$ ) (mmol/l)	1.19	1.20	0.94
pH	7.360	7.362	7.373
$PcO_2$ (mmHg)	39.74	4.20	31.50
Bicarbonate ( $HCO_3$ ) (mmol/l)	23.0	20.4	18.3



**Figure 2.** Barium studies. There is a tight but passable oesophageal stricture distal to the cervicothoracic junction. Esophagus distal to this point shows progressive generalized luminal narrowing, with loss of peristaltic activity with a normal stomach, consistent with a corrosive esophageal stricture.



**Figure 3.** Barium swallow showing a long-segment esophageal narrowing (stricture), with multiple oval filling defects.



**Figure 4.** Oral burns, including lip and tongue erythema, edema, leukoplakia, and ulceration following corrosive ingestion.



below, at home, as well as among children of families of low socioeconomic background. This is in keeping with previous studies which also reported that most cases of accidental caustic ingestion occur in younger children, at homes and nearby.<sup>13,14</sup>

Children under 5 years of age are usually affected because they are not able to make reasonable decisions about what they should or should not drink, in the context of their developmental stage of motor and sensory skills.<sup>15</sup>

Two of the cases in the series occurred in females. However, other studies have reported a higher incidence in males, attributed to probable gender-related biological and learned gender-role behaviors among boys, different from girls in terms of how they express health and disease, and their interaction with risk factors.<sup>16</sup> The higher incidence of girls in our series may be due to fewer numbers seen, and may also be a chance occurrence.

In the second case described, the child was under the custody of the maternal grandmother in a rural setting. Poverty, low maternal education, and lack of adequate maternal supervision are the recurring predisposing factors that make children, particularly the younger ones, accidentally consume these harmful, corrosive substances. Extended family structure, as seen in the second case described, implies crowded living conditions, with increased risk for injury in such home settings, due to inadequate supervision of the child, with regards to caustic substances that mostly do not have warning labels or child-resistant safety caps, as was observed in the cases seen. All these factors, as highlighted, may contribute to accidental caustic ingestion in children.

In this series, caustic soda was the most common agent, usually ingested inadvertently by children. Studies have reported that the common corrosive agents implicated are alkaline products including caustic soda, sodium hypochlorite, and household chemicals.<sup>1,18</sup> In addition, the caustic substances were stored in containers/buckets, which are, in this case, secondary containers with no labels or child lock proofs. It becomes imperative to bring this to bear as most of these products ingested by children were kept in containers with no warning labels and no childproof safety caps. These predisposing factors should be addressed by the national governmental agencies through health education and the implementation of legislative and preventive strategies on the labeling, formulation, and packaging of corrosive products.<sup>13</sup> All three cases in this series were presented late to our facility, which is a referral tertiary center for cardiothoracic surgery in Nigeria and the West African sub-region. This stems mainly from ignorance, as their first port of call was either patent medicine dealers or even self-medications at home. In all the cases, the patients presented late to hospitals after the onset of complications, particularly esophageal stricture, usually appearing with complaints of difficulty in swallowing, initially to solids and later to liquids. The time interval from the ingestion of the corrosive substance to the onset of the features of stricture, as observed in two of the cases reported, was between 17 to 21 days, by which time most of the complications have occurred, as evident from its pathophysiology. Usually, hemorrhage, thrombosis, and a marked inflammatory response with significant edema appear in the first 24 hours of corrosive ingestion injury,<sup>17,18</sup> followed by the tissue repair phase (1<sup>st</sup> week to second week after injury), and if the injury is minor, esophageal function usually returns gradually. The healing phase then follows by the 3<sup>rd</sup> week of the injury, as fibroblast proliferation replaces the submucosa and *muscularis mucosae*, and then stricture formation starts.<sup>18</sup> Furthermore, presentation to patent medicine stores or use of self-medications at home may lead to some harmful practices that may worsen the prognosis of such cases. Two of the cases were given palm oil/coconut oil per oral to neutralize the ingested

caustic substances. Induction of emesis using syrup of ipecac after a caustic ingestion should be discouraged, as it could further expose the esophagus to the corrosive substance. The same applies to any liquids applied either to dilute or neutralize the caustic agent, including the use of palm oil or coconut oil, as this practice could result in vomiting.<sup>19</sup> The children developed oral burns (ulcers), including lip or tongue erythema and edema, leukoplakia, or ulceration ulcers, and later within two to three weeks following the ingestion of the corrosive substances, developed difficulty in swallowing, initially to solids and later liquids, as have been corroborated in similar studies.<sup>14,16,19</sup>

Barium swallow was done for the first two cases and reported findings consistent with esophageal stricture, while the third case presented in the acute phase with pulmonary complications and was managed in the pediatric intensive care unit, but succumbed due to the severity of the case.

Gastrointestinal endoscopy was done for the second case. Pediatric endoscopy for caustic ingestion should ideally be performed under general anesthesia with a protected airway, and not as an elective procedure on an outpatient basis. The essence of the endoscopy is to grade the esophageal injury early and help to prognosticate the injury. The endoscopy should also be carried out early in the disease to avoid the risk of esophageal perforation, usually within the first 1-4 days following the event.

One of the cases received corticosteroid therapy in a patent medicine shop. One could doubt the audacity of such a facility giving steroids, considering their potential capacity. However, corticosteroid therapy in acute corrosive injury is controversial. The assumption is that it will prevent stricture formation through a reduction in fibroblast formation in individuals with grade 2 or 3 injuries. Corticosteroid administration in corrosive injury has not shown any benefit in the meta-analysis and has remained a controversial modality of treatment.<sup>20</sup>

Some patients in our series received surgical gastrostomy for feeding, in order to meet their daily nutritional requirements, as well as fluids. Also, serial esophageal dilations were planned for two of the cases in our series at the time of writing this report. Topical mitomycin-C application could be applied to augment endoscopic dilatation for short esophageal strictures, and esophageal stents and balloon dilators are known options for treating strictures.<sup>21</sup> A few cases of esophageal strictures refractory to dilation may need replacement by a colonic graft or stomach plasty to set up a gastric tube. Ezemba *et al.*<sup>22</sup>, previously in UNTH, Enugu, reported a retrospective study of 21 patients with subteral isoperistaltic colonic interposition graft for the management of corrosive esophageal stricture.

Public education on the importance of adequate supervision of younger children and the risks imposed on the environment is crucial for the prevention of unintentional corrosive ingestion and its associated complications. Public health awareness campaigns using various media are equally needed to lobby governments at both sub-national and national levels to legislate appropriate safety regulations in our setting.<sup>17</sup>

In addition to health education, lobbying of the relevant stakeholders has led to the development and implementation of protective legislation in Western countries, as evidenced by manufacturers' producing child-proof bottle tops, requiring the application of focal pressure in addition to unscrewing the cap, limitation on pH of detergents marketed for domestic use and package labeling requirements of content of chemicals.<sup>17</sup>

One area that is still begging for answers in our setting is the household use of strong industrial-strength caustic substances, usually for home soap making. Often times these agents are sold or

decanted and stored in non-descript plastic containers, including buckets often used in storing drinking water in most homes. The danger posed by this practice is that thirsty children could mistake the content for drinking water or be given the same by unsuspecting older siblings trying to assist them as well.

## Conclusions

In conclusion, unintentional corrosive ingestion could occur in children, particularly those about 3 years of age, mostly at home, with these harmful chemicals stored in containers/buckets (secondary containers), with no labeling or child lock proofs. In addition, most of these children developed esophageal stricture.

There is a need for targeted health education to parents to control the factors that predispose their younger children to possible caustic substance ingestion and to seek care in standard healthcare facilities in our setting. Also, the government should continue to train and retrain patent medicine dealers while regulating their limits of practice. In addition, the government should enact the necessary legislation to control the production and handling of all corrosive substances.

## References

- Dogan Y, Erkan T, Cullu F, Kutlu T. Caustic gastro esophageal lesions in childhood: an analysis of 473 cases, *Clin. Pediatr* 2006;45:435-8.
- Othman N, Kendrick D. Epidemiology of burn injuries in the East Mediterranean Region: A systematic review. *BMC Public Health* 2010;10:83.
- Bronstein AC, Spyker DA, Cantilena LR Jr, et al. 2011 Annual Report of the American Association of poison control centers' national poison Data system (NPDS): 29th Annual report. *Clin Toxicol (Phila)* 2012;50:911-1164.
- Karaman I, Koc C, Karaman A, et al. Evaluation of 968 children with corrosive substance ingestion. *Indian J Crit Med* 2015;19:714-8.
- Contini S, Tesfaye M, Picone P, et al. Corrosive esophageal injuries in children. A short lived experience in Sierra Leone. *Int J. Pediatr Otorhinolaryngol* 2007;71:1597-604.
- Rafeey M, Ghojzadeh M, Mehdizadeh A, et al. Intercontinental Comparison of caustic ingestion in children. *Korean J Pediatr* 2015;58:491.
- Tiryaki T, Livaneloglu Z, Atayurt H. Early bougienage for the relief of stricture formation following caustic esophageal burns. *Pediatr Surg Int* 2015;21:78-80.
- Muller AJ, Cox SG. Caustic injury of the esophagus. *Pediatr Surg Int* 2015;31:111-21.
- Ogunleye OA, Nwaorgu OGB, Grandawa A. Corrosive oesophagitis in Nigeria: clinical spectrums and implications. *Tropical Doctor* 2002;32:78-80.
- Adegboye VO, Brimmo A, Adebo OA. Trans-hital oesophagectomy in children with corrosive stricture. *African Journal of Medicine and Medical Sciences* 2000;29:223-6.
- Ekpe EE, Ette V. Morbidity and mortality of caustic ingestion in rural children: experience in a new cardiothoracic surgery unit in Nigeria. *International Scholarly Research Network. ISRN Pediatrics* 2012;2012:210632.
- Jassen TL, van Dijk M, van As AS, et al. Cost-effectiveness of the sucralfate technetium 99m isotope- labelled oesophageal scan to assess esophageal injury in children after caustic ingestion. *Emerg Med Open J* 2015;1:17-21.
- Sanchez-Ramirez CA, Larrosa-Haro A, Va´ squez-Garibay EM, Maci as-Rosales R. Socio-demographic factors associated with caustic substance ingestion in children and adolescents. *International Journal of Pediatric Otorhinolaryngology* 2012;76:253-6.
- Urganci N, Usta M, Kalyoncu D, Demirel E. Corrosive substance ingestion in children. *Indian Journal of Pediatrics* 2014;81:675-9.
- Gundogdu H, Tanyel F, Buyukpamukcu N, Hicsonmez A. Conservative treatment of caustic oesophageal strictures in children. *Journal of Pediatric Surgery* 1992;27:767-70.
- Hamza A, Abdelhay S, Sherif H, et al. Caustic esophageal stenosis in children: 30 year experience. *Journal of Pediatric Surgery* 2003;38:828-33.
- Arnold M, van As AB, Numanolu A. Pattern of ingestion injuries in children. *S. Afr Med J* 2017;107:183-7.
- Kay M, Willye R. Caustic ingestion in children. *Current Opinion in Pediatrics* 2009;21:651-4.
- Ertekin C, Alimoglu O, Akyildiz H, et al. The results of caustic ingestions. *Hepato- gastroenterology* 2004;51:1397-400.
- Pelcova D, Navrátil T. Do corticosteroids prevent oesophageal stricture after corrosive ingestion? *Toxicological Reviews* 2005;24:125-9.
- El-Asmar K, Hassan M, Abdelkader H, Hamza A. Topical mitomycin C can effectively alleviate dysphagia in children with long-segment caustic esophageal strictures. *Diseases of the Esophagus* 2015;28:422-7.
- Ezamba N, Eze J, Nwafor I, et al. Colon inter-position graft for corrosive esophageal stricture: Midterm functional outcome. *World Journal of Surgery* 2014;38:2352-7.