

Gossypiboma, a rare cause of failure in surgical intervention: a case report and review of literature

Francis I. Ukekwe,¹ Onyekachi C. Nwokoro,¹ Celestine E. Nnamani,² Isaiah O. Nwidenyi,³ Ikechukwu Ugwueke²

¹Department of Morbid Anatomy, University of Nigeria, Enugu Campus/University of Nigeria Teaching Hospital, Enugu;

²Department of General Surgery, University of Nigeria Teaching Hospital, Enugu;

³Department of Morbid Anatomy, University of Nigeria Teaching Hospital, Enugu, Nigeria

Abstract

Gossypiboma (GB) is a rare but avoidable cause of failure in surgical intervention due to the retention of a surgical swab in the body after an operation. It leads to potentially fatal complications with far-reaching medico-legal implications. We report a case of a 28-year-old female who presented with a month history of severe abdominal pain following a myomectomy surgery. Abdominopelvic ultrasound and Computed Tomography (CT) reported an ill-defined mass in the abdomen. Exploratory laparotomy revealed extensive peritoneal adhesions, and a hard mass walled off by the greater omentum and adherent to the jejunum.

Histopathological evaluation of the excised mass showed gauze-like material surrounded by intense granulomatous inflammation, adherent to intestinal segments. She was subsequently treated with ceftriaxone, metronidazole, and pentazocine and discharged home after an uneventful postoperative period.

Introduction

Gossypiboma (GB) is a term derived from the combination of the Latin word “gossypium” (meaning “cotton”) and a Swahili word “boma” (meaning “place of concealment”).¹ It is a rare complication of surgery and describes the retention of a mass of cotton material after an operation.^{1,2} The cotton material usually retained in the body include; gauze, sponges and towels.² This condition can arise after any type of surgery^{3,4} but most commonly occurs after intra-abdominal or pelvic surgeries.⁵ It is also commoner after emergency surgeries, change in plan of an operation on the table, high Body Mass Index (BMI), inadequate attention to sponge count, and profuse bleeding in which gauze swabs are used to achieve haemostasis.⁶ This rare and unfortunate condition can cause potentially fatal complications and suddenly upset the lives of both the patient and the surgeon.^{7,8} Clinicians and pathologists must have a high index of suspicion of this condition for early diagnosis, prevention of morbidity and proper reporting because of the medico-legal implications.⁷ This article was previously presented as a meeting abstract at the 2022 Annual General Meeting of the Enugu State Nigeria Medical Association on October 25, 2022.

Case Report

A 28-year-old nulliparous Nigerian female presented at our surgery clinic with a month history of severe abdominal pain following a myomectomy surgery at a peripheral hospital for uterine fibroids. No associated history of weight loss, menorrhagia nor abdominal swelling. On clinical examination was a young lady, conscious and alert but in obvious painful distress. She was afebrile, mildly pale, anicteric, not cyanosed, no pedal edema but was moderately dehydrated. The respiratory rate was 60 breaths per minute, pulse rate 120 beats per minute and blood pressure 100/70 mmHg. The abdomen was flat, moved with respiration, and with generalized abdominal tenderness. The examination of the liver, spleen, and kidneys were unremarkable. An impression of acute abdomen was made and an urgent abdominopelvic ultrasound requested. The preoperative laboratory investigation results were hemoglobin concentration 10 g/dL, serum electrolyte concentration sodium (Na⁺) 138 mmol/L, potassium (K⁺) 4.1 mmol/L, bicarbonate (HCO₃⁻) 20 mmol/L, chloride (Cl⁻) 108

Correspondence: Francis I. Ukekwe, Department of Morbid Anatomy, University of Nigeria, Enugu Campus/University of Nigeria Teaching Hospital, Enugu, Nigeria.
E-mail: francis.ukekwe@unn.edu.ng

Key words: gossypiboma, granuloma, pathology, gauze, surgery.

Contributions: all the authors made a substantive intellectual contribution. All the authors have read and approved the final version of the manuscript and agreed to be held accountable for all aspects of the work.

Conflict of interest: the authors declare no potential conflict of interest.

Funding: none.

Availability of data and materials: all data generated or analyzed during this study are included in this published article.

Received: 17 July 2023.

Accepted: 4 August 2023.

Early access: 11 September 2023.

This work is licensed under a Creative Commons Attribution NonCommercial 4.0 License (CC BY-NC 4.0).

©Copyright: the Author(s), 2023

Licensee PAGEPress, Italy

Annals of Clinical and Biomedical Research 2023; 4:537

doi:10.4081/acbr.2023.537

Publisher's note: all claims expressed in this article are solely those of the authors and do not necessarily represent those of their affiliated organizations, or those of the publisher, the editors and the reviewers. Any product that may be evaluated in this article or claim that may be made by its manufacturer is not guaranteed or endorsed by the publisher.

mmol/L, and negative HIV 1 and 2 antibodies. An ill-defined mass was seen on abdominopelvic ultrasound, which was better characterized by Computed Tomography (CT) scan as a foreign-body in the mesentery. An exploratory laparotomy was done which showed extensive peritoneal adhesions, and a hard mass walled off by the greater omentum and adherent to the jejunum. Excision of the mesenteric and intestinal masses was done and sent for histopathological evaluation. The gross examination of the specimen showed two adherent intestinal segments measuring 15.0cm and 11.0cm long

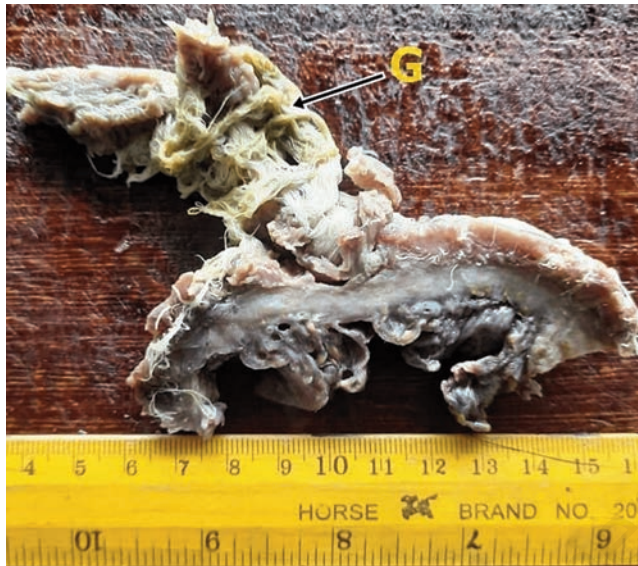

Figure 1. Biopsy specimen. Photograph of a cut section of the biopsy specimen showing small bowel wall with adherent gauze [G] material.

with pieces of gauze-like material deeply embedded in their serosal surfaces (Figure 1, Figure 2). The microscopic examination of sections of the specimen showed strands of amorphous material surrounded by intense granulomatous inflammation containing several foreign bodies and Langhans type multinucleated giant cells adherent to intestinal segments (Figures 3-7). She was subsequently treated with ceftriaxone, metronidazole and pentazocine and discharged

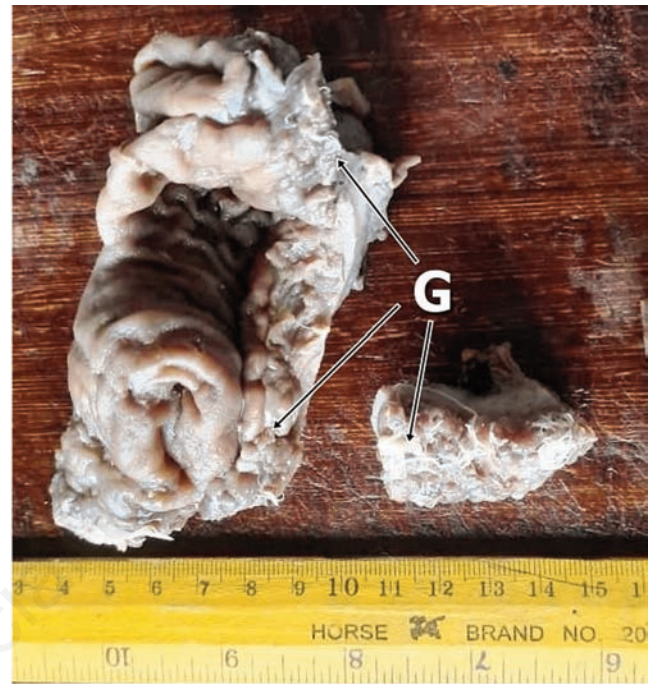

Figure 2. Biopsy specimen. Photograph of a cut section of the biopsy specimen showing a small bowel wall with adherent gauze [G] material.

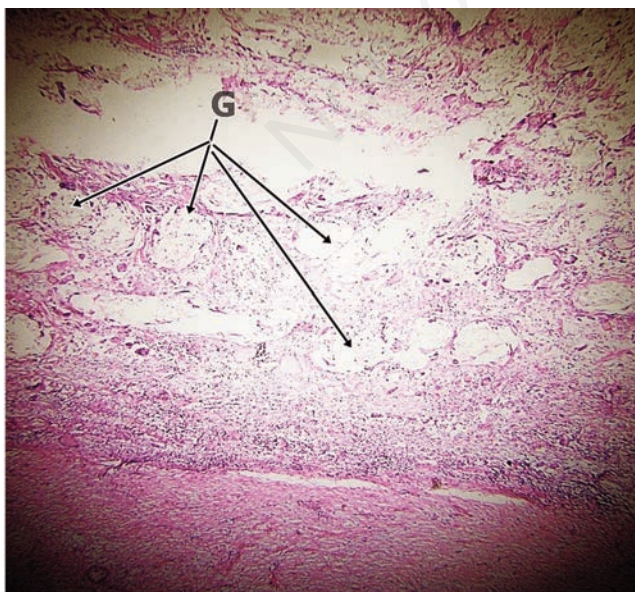


Figure 3. Microscopy. Photomicrograph showing strands of amorphous material [G] surrounded by intense granulomatous inflammation and adherent to wall of small bowel (H & E x 40).

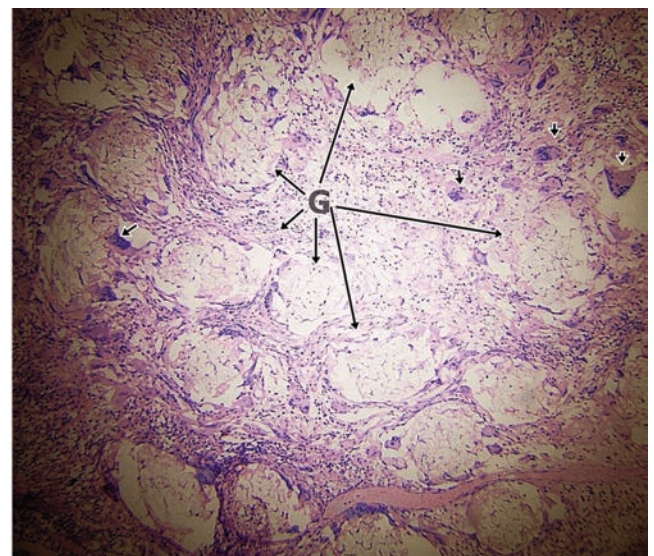


Figure 4. Microscopy. Photomicrograph showing wall of small bowel with adherent strands of amorphous material [G] surrounded by intense granulomatous inflammation containing several foreign body type multinucleated giant cells [small arrows] (H & E x 100).

home after an uneventful postoperative period. At a follow-up, two months later, patient was stable and there were no complaints.

Discussion

The incidence of retained foreign bodies such as sponge, needle, or any part of instrument following surgery is estimated to be 0.01%-0.001%,⁸ and GB constitutes about 80% of these foreign body cases.⁹ GB is an avoidable condition that can pose serious morbidity and mortality problems.^{6,10} The exact incidence of GB is difficult to establish in clinical practice due to underreporting of such cases due to fear of litigation.^{8,10-11} It is however, reported to be one in 100-5000 for all surgical interventions and one in 1000-1500 for intra-abdominal operations.¹² Abdominal GB may be asymptomatic or may present with abdominal pain, abdominal mass, intestinal obstruction, gastrointestinal hemorrhage, intra-abdominal sepsis, granulomatous peritonitis, and fistulation into surrounding structures.^{13,14} The symptoms of GB are usually nonspecific and may appear months to years after surgery, thus the diagnosis of GB usually comes from imaging studies and a high index of suspicion by the attending physician.¹³ In most advanced countries, surgical sponges contain radiopaque material (Ray-tec sponges) that facilitates detection by standard abdominal radiography. Such sponges can also be identified readily in CT images.¹⁴ However, in developing countries like ours where most of the population are living in poverty, most patients cannot afford such tagged sponges and thus any accidentally retained sponges becomes difficult to identify through simple radiological investigations such as plain X-rays. Abdominal CT is the best imaging modality in making the diagnosis, indicating the exact location of GB and precisng its possible complications.¹⁰ This comes with its additional cost implications and thus intensified efforts to avoid such occurrences should be emphasized. It is also imperative for retained foreign body to be considered a differential diagnosis in all postoperative patient presentations of pain, infection, palpable mass or unusual symptoms.¹⁵ Pathologists should always look out

for foreign bodies in biopsy specimen sent to them for evaluation and be willing to report such findings in their reports. Under reporting of such findings have a negative effect on patient care and audit of clinical practice.

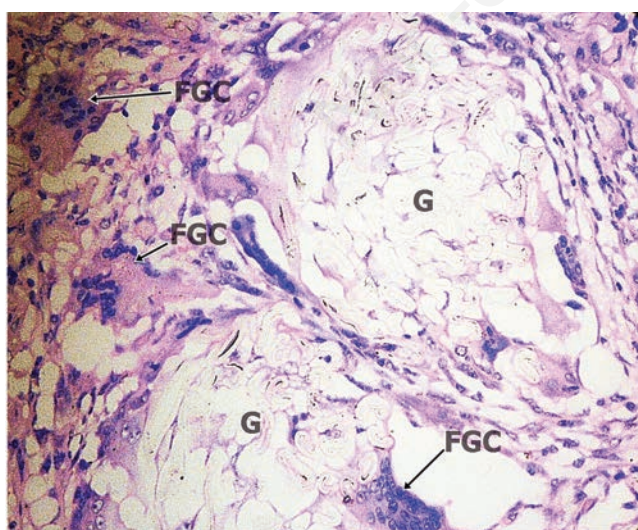


Figure 5. Microscopy. Photomicrograph showing wall of small bowel with adherent strands of amorphous material [G] surrounded by intense granulomatous inflammation containing several foreign body type multinucleated giant cells [FGC] (H & E x 400).

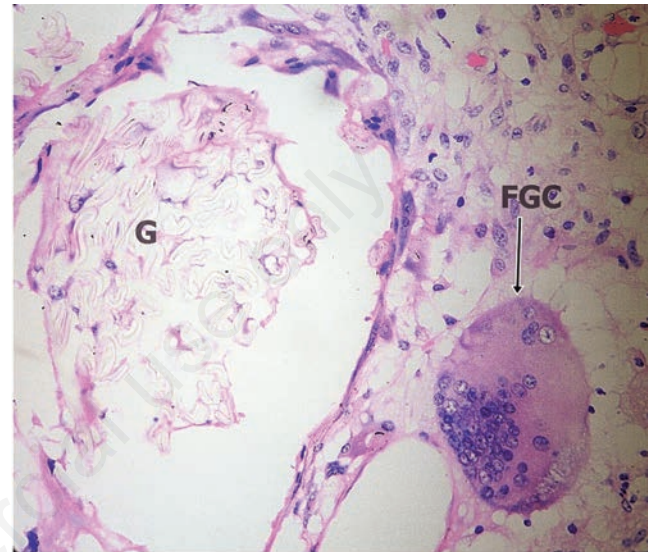


Figure 6. Microscopy. Photomicrograph showing wall of small bowel with adherent strands of amorphous material [G] surrounded by intense granulomatous inflammation containing several foreign body type multinucleated giant cells [FGC] (H & E x 400).

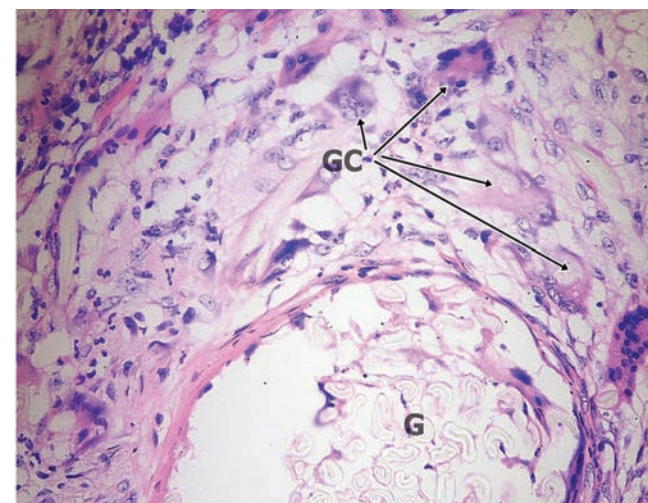


Figure 7. Microscopy. Photomicrograph showing wall of small bowel with adherent strands of amorphous material [G] surrounded by intense granulomatous inflammation containing several multinucleated giant cells [GC] (H & E x 400).

Conclusions

GB is an unusually rare but important postsurgical complication even in apparently successful surgical interventions. While strict adherence to standardized surgical operating procedures and operating room management protocols would reduce its occurrence, a high index of suspicion, early diagnosis and treatment would reduce the significant morbidity and eventual mortality associated with this condition. Proper histopathological evaluation and reporting should always be done because of its medico-legal implications.

References

1. Sun HS, Chen SL, Kuo CC, et al. Gossypiboma—Retained Surgical Sponge. *J Chin Med Assoc* 2007;70:511-3.
2. Aminian A. Gossypiboma: a case report. *Cases J* 2008;7:220.
3. Sheehan RE, Sheppard MN, Hansell DM. Retained intrathoracic surgical swab: CT appearances. *J Thorac Imaging* 2000;15:61-4.
4. Ebner F, Tölly E, Tritthart H: Uncommon intraspinal space occupying lesion (foreign-body granuloma) in the lumbosacral region. *Neuroradiology* 1985;27:354-6.
5. Manzella A, Filho PB, Albuquerque E, et al. Imaging of gossypibomas: pictorial review. *AJR Am J Roentgenol* 2009;193:94-101.
6. Lata I, Kapoor D, Sahu S. Gossypiboma, a rare cause of acute abdomen: a case report and review of literature. *Int J Crit Illn Inj Sci* 2011;1:157-60.
7. Enugu State Nigeria Medical Association. Abstracts of the Annual General Meeting of the Enugu State Nigeria Medical Association, 2022. *Ann Clin Biomed Res* 2022;3:303.
8. Gothwal M, Rodha M, Surekha B, et al. Gossypiboma: A Nightmare for Surgeon: A Rare Case with Review of Literature. *J Midlife Health* 2019;10:160-2.
9. El Zemity H, Hakami N, Alfaki MA, et al. Intra-Abdominal Gossypiboma: A Rare Cause of Palpable Abdominal Mass with a Review of Literature. *Cureus* 2020;12:e10930.
10. Mejri A, Arfaoui K, Aloui B, Yaakoubi J. Gossypiboma: the failure of a successful intervention. *Pan Afr Med J* 2020;25:335.
11. Kumar P, Shukla P, Tiwary SK, et al. Gossypiboma: An avoidable but not a rare complication. *Proceedings of Singapore Healthcare* 2021;30:330-3.
12. Gawande AA, Studdert DM, Orav EJ, et al. Risk factors for retained instruments and sponges after surgery. *N Engl J Med* 2003;16:229-35.
13. Sümer A, Carparlar MA, Uslukaya O, et al. Gossypiboma: retained surgical sponge after a gynecologic procedure. *Case Rep Med* 2010;917626.
14. Peyrin-Biroulet L, Oliver A, Bigard MA. Gossypiboma successfully removed by upper-GI endoscopy. *Gastrointest Endosc* 2007;66:1251-2.
15. Garg MK, Zeya MT, Garg U, et al. Gossypiboma a diagnostic dilemma or medical negligence a case report. *Journal of Indian Academy of Forensic Medicine* 2014;36:100-3.