

## Idiopathic orbital inflammation: An unusual presentation of benign essential blepharospasm

Aliyu Ibrahim,<sup>1</sup> Musbahu Sani Kurawa,<sup>2</sup> Shuaibu Abdulsalam,<sup>2</sup> Yusuf Lawal<sup>3</sup>

<sup>1</sup>Neurology Unit, Department of Medicine, <sup>2</sup>Department of Ophthalmology, <sup>3</sup>Department of Radiology, Faculty of Clinical Sciences, Bayero University, Kano, Nigeria

### Abstract

A case of a 48-year-old man with recurrent twitching of the right eye associated with the drooping of the upper eyelid, ipsilateral periorbital headache and blurring of vision aggravated by direct exposure to strong sunlight. Eye examination revealed intermittent twitching of the right upper eyelid, mild restriction of range of motion (downward gaze) and difficulty reading small prints (presbyopia). Computed tomographic scan showed thickened right superior rectus muscle and tendons. Based on the clinical and neuroimaging abnormalities a diagnosis of right orbital myositis inflammation was made. Patient was given high dose oral corticosteroids and remarkable improvement in his symptoms was recorded after 6 weeks of treatment.

### Introduction

Idiopathic orbital inflammation (IOI), also known as orbital inflammatory pseudotumor is an uncommon benign non-specific orbital space-occupying inflammatory condition, which commonly involves the extraocular muscles (EOMs) and may clinically mimic a neoplasm. The typical presentation is unilateral but bilateral involvement is not uncommon.<sup>1</sup>

The size and location of the lesions vary and may cause variable mild to severe problems including diplopia, conjunctival chemosis, proptosis or visual loss.<sup>2</sup> A clinical classification based on location has been proposed into; myositis, lacrimal, anterior, apical (posterior) or diffuse pseudotumour.

Diagnosis is based on careful history, detailed eye examination, and imaging investigations which may include orbital ultrasonography (B-scan), CT-scan and magnetic resonance imaging (MRI) studies to establish the diagnosis and provide prognostic information. Confirmation is made

by tissue biopsy, which is highly invasive and advised only in atypical presentations.<sup>3</sup>

Systemic corticosteroids are generally considered as mainstay for treatment of idiopathic orbital inflammatory disease.<sup>4</sup> However, in refractory cases immunosuppressive agents, radiation and even biologic therapy have been found to be useful in the management. In this article we report an adult Nigerian male with idiopathic orbital inflammation unusually presenting with features suggestive of benign essential blepharospasm.<sup>5</sup>

### Case Report

A 48-year-old male accountant of a local airline company presented with one-year history of progressive increase in twitching of the right upper eyelid. Each episode lasts less than 5 minutes. It was associated with ipsilateral eyelid drooping, eye discomfort, occasional diplopia, and a dull periorbital headache, which was aggravated by eye movement and exposure to intense sunlight. No preceding history of blurring of vision, tearing, eye swelling, redness or itching of the eyes. No history of fever, dysphagia, nasal blockage, earache, or trauma to the eye. No associated history of dysphagia, change in voice, shortness of breath, palpitations, heat intolerance, neck swelling, hand tremors or rashes. No history suggestive of arthralgia, weakness or swelling elsewhere in the body, and no history of use of any systemic or topical medications. He had no history of past hospitalisation, hypertension or diabetes mellitus. General physical examination was within normal limits. Cardiovascular examination: Pulse rate of 82 beats per minute, BP = 110/70 mmHg (sitting) with normal heart sounds. Eye examination revealed intermittent twitching of the right upper eyelid, no palpable orbital mass, with some restriction of range of extraocular muscle movement (EOMM) on downward gaze inferonasally (Figure 1). The cornea and lens were clear, anterior chambers were deep, with normal pupillary size and reaction to light in both eyes. Funduscopy showed a flat retina, pink disc with distinct margins, normal vessels and macula with CDR of 0.3, in both eyes. Intraocular pressure (IOP) assessment: right eye 20 mmHg, left eye 18 mmHg. Presenting Visual Acuity: Right eye 6/6. Left eye 6/6-1, Near Vision N36 (presbyopic). Exophthalmometry: right Eye 22 mm and left Eye 19 mm at a lateral intercanthal distance of 130 mm. Optical coherence tomography (OCT) was essentially within normal limits. The following were result of investigations carried out: Fasting blood

Correspondence: Aliyu Ibrahim, Neurology Unit, Department of Medicine, Faculty of Clinical Sciences, Bayero University, Kano at Aminu Kano Teaching Hospital, No 1 Zaria Road, PMB 3452, Kano-Nigeria. E-mail: aliyubng@yahoo.com

Key words: blepharospasm, pseudotumor, orbital, inflammatory.

Contributions: AI conceived the study design, AS did the literature search; AI, MSK and YL obtained the data, AI, AS, MSK and YL drafted and revised the article for intellectual content. All authors approved the final version of the manuscript to be published.

Conflict of interest: the authors declare no potential conflict of interest.

Funding: none.

Received for publication: 3 September 2019. Revision received: 4 March 2019. Accepted for publication: 30 May 2019.

This work is licensed under a Creative Commons Attribution NonCommercial 4.0 License (CC BY-NC 4.0).

©Copyright: the Author(s), 2019

Licensee PAGEPress, Italy

Pyramid Journal of Medicine 2019; 2:24

doi:10.4081/pjm.2019.24

glucose (FBG) – 3.5 mmol/L, Thyroid function tests (TFT): T3 – 3.58 [3.2-6.8] nmol/L, T4 – 12.22 [10.2-26.4] nmol/L, TSH – 4.01 mU/L. Stool examination for helminths: Macroscopy - a well formed dark brown stool was collected, no mucus, blood, or adult worm(s) seen. Microscopy – 2 to 3 pus cells were present, no cyst or ova of parasite seen and culture isolated no organism. Brightness mode scan (B-scan) result showed a right anteroposterior (AP) globe and optic nerve head diameters of 23.1 mm and 2.8 mm respectively, and a left AP globe diameter and optic nerve head of 22.1 mm and 2.8 mm respectively. No intraocular mass lesion seen in both globes (Figure 2). Cranial CT scan of the orbits showed isolated thickening with decreased attenuation of the entire length of the right superior rectus muscle in keeping with an inflammatory process. It measured 14.0 mm by 9.1 mm in its maximum CC and transverse dimensions (Figure 3). The remaining EOM, periorbital fat space and left orbit are within normal limits. No focal intracerebral mass lesion seen. Findings were suggestive of right orbital myositis inflammation.

Patient was commenced on empirical trial of prednisolone 30 mg bid for 6 weeks. He was also advised on regular use of sun-

glasses to reduce the photo-oculodynia. After 6 weeks, symptoms of right ocular twitching remarkably improved with absence of periorbital headache and diplopia. Repeat eye examination revealed residual mild right blepharoptosis, both eyes are well-aligned with clear cornea and lens, deep anterior chambers, normal pupillary reaction and full range of EOMM in all positions of gaze.

## Discussion

Idiopathic orbital inflammation is an uncommon clinical entity and a diagnosis of exclusion first described by Gleason in 1903 and characterised as a pathology by Birch-Hirschfeld in 1905. It is a heterogeneous disorder characterized by orbital inflammation without any identifiable local or systemic aetiology.<sup>2</sup> Rootman and Nugent subclassified it according to location or structure into 5 patterns: 1. Anterior (which presents with a palpable orbital mass) 2. Lacrimal (dacryoadenitis) 3. Apical or posterior (presents with proptosis, visual loss or even cranial nerve palsies) 4. Myositic (presents with limited EOM motility and diplopia) and 5. Diffuse (may present with diplopia, minimal proptosis, conjunctival injection, chemosis and periorbital edema). Although the cause is unknown, its association with autoantibodies active against eye muscle membrane proteins of 55 and 66 kilodaltons postulated an immune-mediated pathophysiologic mechanism.<sup>6</sup> It is a common cause of unilateral proptosis in middle-aged females that may present with painful ophthalmoplegia and conjunctival edema. However, as a cause of acquired retraction of the eye is rare, our case therefore emphasized the importance of globe retraction as an important clue for its diagnosis.<sup>7</sup> Acute and subacute form of the disorder usually present with normal function, paretic or combined paretic and restrictive transient myopathies, while the chronic form presents with permanent restrictive myopathies.<sup>8</sup> Imaging of the orbit (ultrasound, CT scan, MRI) may show swollen EOMs with enlarged tendons due to orbital myositis as against grave's ophthalmopathy where the tendons are usually spared. The role of ocular muscle biopsy is probably limited to atypical cases or to exclude neoplasia. The cornerstone of treating idiopathic orbital inflammation entails the use of systemic steroids. Dramatic response is seen in over 75% of patients within 24 to 48 hours of treatment.<sup>9</sup> Starting doses of Prednisone of 1.0 to 2.0 mg/kg/day are adequate with slow tapering guided by therapeutic response. Additionally, intraorbital injection of steroids have been found to

be effective when used as first-line in some selected patients.<sup>10</sup> The acute form usually responds well to high doses of oral corticosteroids, while response is less optimal with the subacute and chronic forms of the disorder. Other therapeutic options in cases of recalcitrant or recurrent variants is the use of cytotoxic agents (Cyclophosphamide, Chlorambucil), immunosuppressants

(Methotrexate, Cyclosporine, Azathioprine, Mycophenolate mofetil), monoclonal antibody directed against TNF-alpha (Infliximab and adalimumab) and low dose radiation especially where conventional treatment fails. Earlier studies of orbital pseudotumour in Nigeria were mainly from histopathologic confirmation of excised surgical specimens of orbital proptosis,<sup>11,12</sup>

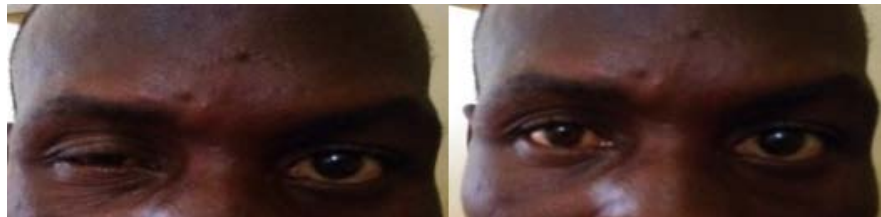

Figure 1. Right eyelid blepharospasm.

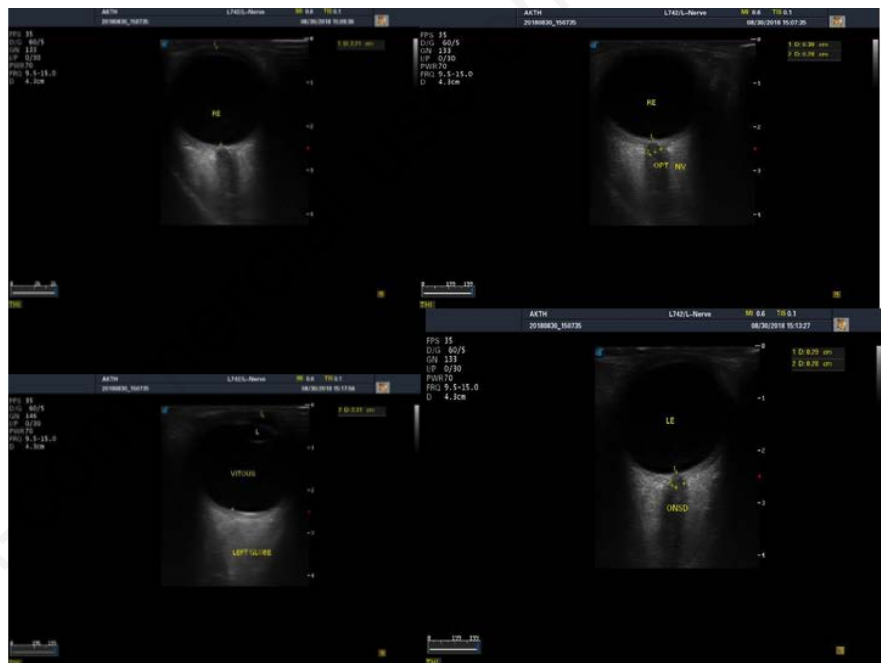


Figure 2. Ocular B-mode scan ultrasound images showing normal posterior segments and optic nerve head dimensions.

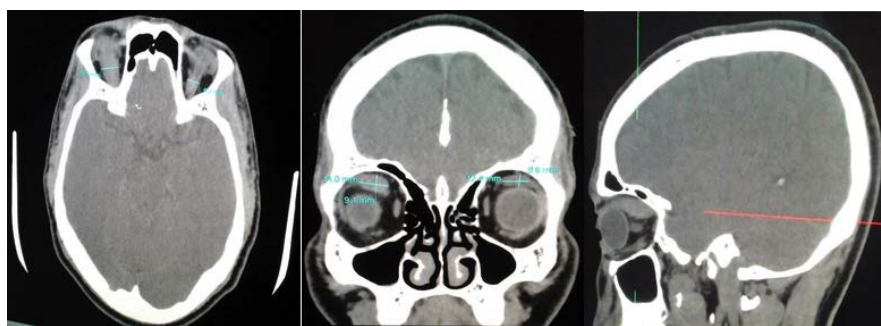

Figure 3. Cranial CT scan (Axial, Coronal and Sagittal views) showing right superior rectus muscle enlargement suggestive of idiopathic orbital inflammation.

which is in contrast to our patient who had an unusual clinical presentation of unilateral essential blepharospasm with imaging evidence of superior rectus muscle inflammation. Although tissue biopsy was not done in our case because there was no strong indication for this invasive procedure, and the significant improvement with corticosteroids strongly favoured this diagnosis. Blepharospasm usually manifest as involuntary contraction of the orbicularis oculi due to over activity of the facial nerve, which may result from conditions such as painful ocular diseases (blepharitis, iritis, pan-ophthalmritis), multiple sclerosis, or glioma around the facial nerve nucleus in the dorsal pons. The mainstay of treatment is quarterly injection of Botulinum toxin-A as other medical treatment and surgical options have been less than optimal.

### Conclusions

Our report highlighted idiopathic orbital inflammation as an unusual presentation of essential blepharospasm which should

always be considered as a differential diagnosis in general clinical practice.

### References

1. Ahn Yuen SJ, Rubin PAD. Idiopathic Orbital Inflammation Distribution, Clinical Features, and Treatment Outcome. *Arch Ophthalmol* 2003;121:491-9.
2. Kamili MA, Ali G, Dar IH, et al. Orbital pseudotumor. *Oman J Ophthalmol* 2009;2:96-9.
3. Gordon LK. Orbital inflammatory disease: a diagnostic and therapeutic challenge. *Eye* 2006;20:1196-206.
4. Jacobs D, Galetta S. Diagnosis and management of orbital pseudotumor. *Curr Opin Ophthalmol* 2002;13:347-51.
5. Chaudhry IA, Shamsi FA, Arat YO, Riley FC. Orbital Pseudotumor: Distinct Diagnostic Features and Management. *Middle East Afr J Ophthalmol* 2008;15:17-27.
6. Attarian S, Fernandez C, Azulay JP, et al. Clinical and radiological features and clinical course of orbital myositis. *Rev Neurol* 2003;159:307-12.
7. Kargi SH, Atasoy HT, Sayarlioglu H, et al. Acquired retraction of the eye as the first sign of myositis. *Strabismus* 2005;13:85-8.
8. El Ouafi N, Rafai MA, Fadel H, et al. Bilateral idiopathic orbital myositis. *Rev Neurol* 2006;162:750-2.
9. Harris GJ. Idiopathic orbital inflammation: a pathogenetic construct and treatment strategy: The 2005 ASOPRS Foundation Lecture. *Ophthalm Plast Reconstr Surg* 2006;22:79-86.
10. Leibovitch I, Prabhakaran VC, Davis G, Selva D. Intraorbital injection of triamcinolone acetonide in patients with idiopathic orbital inflammation. *Arch Ophthalmol* 2007;125:1647-51.
11. Odunfa AO, Odunfa AO (Jr), Ayeni AO. Orbito-Ocular lesions in Sagamu, Nigeria. *J Bio Innov* 2017;6:159-64.
12. Charles NC, James EV. A study of the histopathologic pattern of orbito-ocular disease in a tertiary hospitals in Nigeria. *Sahel Med J* 2014;17:60-4.