

Right destroyed lung due to tuberculosis in a Nigerian child: Case report and review of the literature

Hafsat Umar Ibrahim, Halima Kabir, Mahmoud Gambo Jahun

Department of Paediatrics, Bayero University/Aminu Kano Teaching Hospital, Kano, Nigeria

Abstract

Destroyed Lung Syndrome (DLS) is total lung destruction from recurrent and chronic infections especially Tuberculosis (TB). It is rare in children and associated with chronic morbidity. It presents with chronic cough, progressive difficulty in breathing, hemoptysis and progressive respiratory failure. The pathology of DLS includes lung fibrosis, collapse, tracheal and mediastinal shift. We report the case of a 9 years old girl referred after three courses of anti-TB treatment for suspected TB re-infection with worsening clinical and radiologic features. Investigations revealed a destroyed right lung. Genexpert was initially positive and subsequently along with TB culture was negative. She improved on antibiotics and chest physiotherapy. Destroyed lung though rare in children should be considered in those who despite TB treatment present with worsening clinical and radiologic features. Early diagnosis and multi-disciplinary approach will prevent irreversible lung damage.

Introduction

Destroyed lung is defined as the total destruction of the lung parenchyma secondary to recurrent or chronic inflammation/infection, tumours or vascular abnormalities.^{1,2} Pulmonary Tuberculosis (PTB) is associated with many pulmonary and extra pulmonary complications including destruction of the lungs, however complete destruction of an entire lung is uncommon.³ The disease leads to lung destruction by causing bronchial obstruction, lobar collapse, atelectasis, fibrosis and hyperinflation of the contralateral lung.^{3,4} It is commoner on the left side because the left main bronchus is longer and narrower than the right and has a more horizontal course which makes complete drainage of secretions from the lung difficult.^{3,5} A prevalence of 11% for destroyed lung among patients in Saudi Arabia has been reported.² Of

these, only 7.7% was on the right. Destroyed lung pathology takes a long time to develop and so are more often reported in adults and is uncommon in children.^{2,3}

It presents as chronic cough productive of purulent sputum, hemoptysis, difficulty in breathing and fever. Complications like massive hemoptysis, septicemia, empyema and left to right shunt with pulmonary hypertension could occur.^{3,6} This could lead to respiratory failure and even death.

Radiologic investigations including Computed Tomographic scan (CT scan), bronchoscopy, bronchography, pulmonary angiography and ventilation-perfusion scans help to define structural abnormalities associated with decrease arterial blood flow and increased oxygen tension. These diagnostic tools however are not readily available in low and middle income countries, and when available are quite expensive. Other investigations include a Full Blood Count (FBC), sputum for microscopy, culture and sensitivity, Acid Fast Bacilli and Genexpert for detection of Mycobacterium tuberculosis and rifampicin resistance.

Medical management includes the institution of appropriate antibiotics for secondary bacterial infection and chest physiotherapy. Pneumonectomy is usually the surgery of choice and it is indicated when medical treatment fails, massive hemoptysis and/or respiratory failure.^{1,2,7,8} We report this case of a destroyed right lung in a child which is rare and we discuss the need for high index of suspicion amongst to physicians and other health care workers caring for children with TB on the possibility of this complication.

Case Report

A 9 years old girl presented to the Aminu Kano Teaching Hospital (AKTH), Nigeria with complaints of recurrent fever, cough and increasing difficulty in breathing of two months duration. Two years prior to presentation, she had a positive sputum smear for Acid Fast Bacilli (AFB), bilateral hilar adenopathy on chest radiograph and a positive Genexpert result. She had not received any vaccination. She was diagnosed with PTB and treated using anti-tuberculous drugs (category 1) for six months. A year later, she re-presented to the referral center with the above complaints where she was again treated for PTB for another six months. She was then referred to the DOTs clinic of AKTH, where she was presumed to have tuberculosis reinfection and treated with anti-tuberculous drugs (category 1) for 6 months and pyridoxine without much improvement. TB treatment

Correspondence: Hafsat Umar Ibrahim, Department of Paediatrics, Bayero University/Aminu Kano Teaching Hospital, Kano, Nigeria.
Tel.: +234.8053468677.
E-mail: ibrahimhafsat@ymail.com

Key words: Destroyed right lung; tuberculosis complication; Nigerian child.

Acknowledgements: The authors will like to acknowledge Dr Mansur Yahuza of radiology department, AKTH for reading the chest radiograph and CT scan films.

Contributions: The authors contributed equally.

Conflict of interests: The authors have no conflict of interests to declare.

Availability of data and materials: All data underlying the findings are fully available.

Ethics approval and consent to participate: No ethical committee approval was required for this case report by the Department, because this article does not contain any studies with human participants or animals. Informed consent was obtained from the guardians of the patient included in this study.

Consent for publication: The patient's guardians gave their written consent to use the personal data for the publication of this case report and any accompanying images.

Received for publication: 16 April 2019.
Revision received: 22 August 2019.
Accepted for publication: 22 August 2019.

This work is licensed under a Creative Commons Attribution NonCommercial 4.0 License (CC BY-NC 4.0).

©Copyright: the Author(s), 2021

Licensee PAGEPress, Italy

Pyramid Journal of Medicine 2021; 4:46

doi:10.4081/pjm.2021.46

was extended by two months for a total duration of complete eight months. Subsequently, she was referred to the Paediatric Infectious Disease Clinic because of her failure to clinically improve.

She still had cough and difficulty in breathing. On clinical examination she had tachypnea with respiratory rate of 34 breaths/minute, oxygen saturation of 99% in room air with the and right tracheal deviation. Percussion notes were dull on the right and hyper-resonant on the left. Breath sounds were normal on the left side but absent on the right mid and lower zones. She had a pulse rate of 94 beats/minute with normal first and second heart sounds but the apex beat was in the 3rd intercostal space

on the right just lateral to the sternum. Abdomen was flat and moved with respiration with no tenderness and no palpably enlarged organs. Her weight was 19 kg and her height was 98 cm a z score of <-3 indicating severe wasting and stunting. Her chest radiograph showed right sided lung collapse, fibrosis, tracheal and mediastinal deviation with hyperinflation of the left lung (Figure 1). The full blood count result showed haematocrit of 31.5%, white blood cell count of 6000/L, lymphocytes of 52.4%, granulocytes of 39.7% with an erythrocyte sedimentation rate of 47mm/hr, an improvement from 120 mm/hr when she was first seen at from the referral clinic. Mantoux test showed an induration of 12mm. Genexpert for tuberculosis and rifampicin resistance was negative. TB culture was negative and the Human Immunodeficiency Virus (HIV) screening was negative. She was diagnosed with post tuberculosis right destroyed lung.

Chest CT-scan showed right destroyed lung, tracheal and mediastinal shift to the right, multiple thick walled cavitations in the right middle lobe lung with compensatory hyperinflation of the left lung (Figure 2). She was managed conservatively with antibiotics (Erythromycin-50mg/Kg) and chest physiotherapy. The patient is now 11 months post treatment and on follow up. The severity of her dyspnea and tachypnea has markedly reduced. Her weight has significantly improved and she has resumed school.

Discussion

Destroyed lung is a long term complication of TB which can occur as a result of progression of primary PTB or TB reactivation.^{2,3,5,6,9-13} Patients usually present late, after years of unrecognized TB infection and have poor compliance with treatment.² It is uncommon in childhood due to the chronicity required for the full pathology to unfold.^{2,3,11} The patient reported here was a nine year old with probable TB reactivation which led to destruction of the right lung. Most studies from Nigeria⁹⁻¹¹ and some other parts of the world^{2,3,5,6} have reported TB as the commonest cause of destroyed lung. This however contrasts with studies from Turkey where bronchiectasis was found to be the commonest aetiology for destroyed lungs.^{1,8} Destroyed lung is also reported to be commoner in those that are immunocompromised^{9,13} however, HIV screening was negative in the index patient.

Symptoms of destroyed lung include recurrent cough, difficulty in breathing, persistent sputum, and haemoptysis.^{2,3,6,9} Our

patient presented with recurrent unproductive cough, fever, and difficulty in breathing. This presentation contrasts with the findings by Eren *et al.*⁸ where 76.4% of their paediatric patients had cough with sputum production as the commonest presentation.

Affectation of the left lung is reported as a more common complication of tuberculosis.^{2,3,8} The right lung is less frequently affected.^{2,3,9-11,13} The presence of perihilar nodes is common in African and Asian children with post primary TB infection making them prone to obstruction.^{2,11} This could be attributed to the high burden of infectious diseases in these regions.

Our findings of tracheal and mediastinal shift to the right, multiple thick walled cavitations in the right middle lobe and compensatory hyperinflation of the left lungs are consistent features of a destroyed lung.^{2,3,6,9,10} The CT scan showed distortion of the architecture of the right lung. These

were as observed in previous reports from Nigeria^{9,10} and Saudi Arabia.² Bronchoscopy and angiography investigational studies were not done in this patient. Ventilation perfusion scan presently not available at Aminu Kano Teaching Hospital.

Surgery is considered in patients with massive haemoptysis, respiratory failure and failure of medical treatment. Pneumonectomy is usually done despite associated complications.^{1,2,7,8,11,13} Our patient was managed conservatively because she had no indications for pneumonectomy.

Result of microscopy culture and sensitivity of gastric washings yielded no organism in this case. Mixed aerobic and anaerobic organisms are implicated in recurrent secondary bacterial infections in patients with destroyed lungs. These include *Klebsiella* and *Pseudomonas* spp among aerobes and *Nocardia* and *Aspergillus* spp

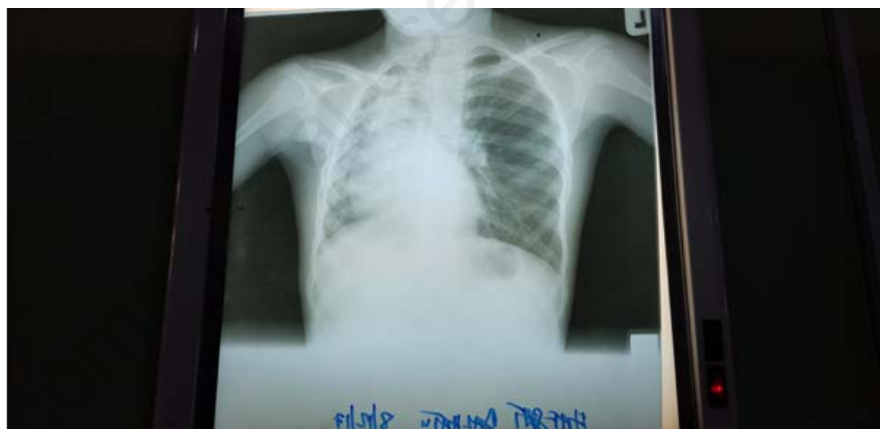

Figure 1. Chest radiograph showing right lung collapse, tracheal and mediastinal shift to the right, fibrosis and hyperinflation of the left lung.

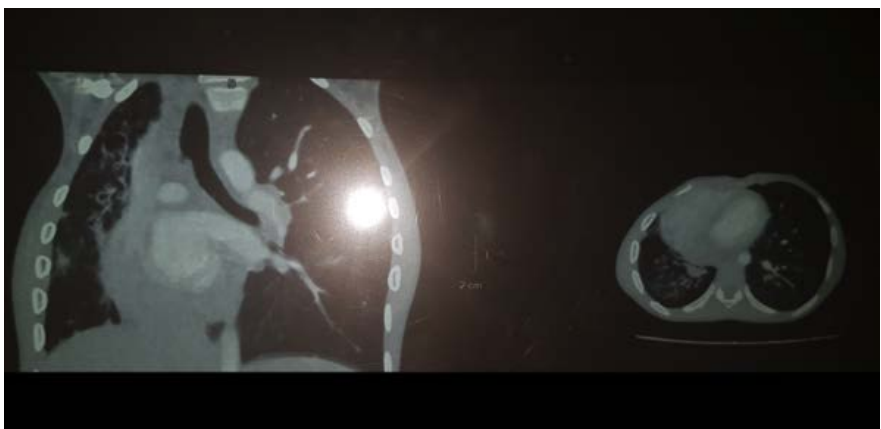


Figure 2. Chest CT-scan showing right destroyed lung, tracheal and mediastinal shift to the right, multiple thick walled cavitations in the right middle lobe lung with compensatory hyperinflation of the left lung.

among anaerobes.^{4,12,14}. Other organisms isolated include fungi like *Cryptococcus neoformans*, *Coccidiomycosis* and *Blastomycosis*, She showed remarkable improvement on antibiotics and chest physiotherapy.

Conclusions

Tuberculous destroyed lung though rare in children should be considered a diagnostic possibility in patients who fail anti-tuberculous treatment and still show worsening respiratory and radiologic features. A detailed and timely clinical and radiological evaluation will guide the clinician to make the diagnosis. Early diagnosis and multi-disciplinary care could prevent irreversible lung damage.

References

1. Kosar A, Orki A, Kiral H et al. Pneumonectomy in children for destroyed Lung: Evaluation of 18 cases. *Ann Thorac Surg* 2010; 89: 226-31
2. Ashour M, Pandya L, Mezraqji A, et al. Unilateral Post TB lung disease- the left bronchus syndrome. *Thorax* 1990; 45: 210-12
3. Varona PD, Persiva O, pallisa E, Andieu J. Radiologic findings of unilateral tuberculous lung destruction. *Insights imaging*, 2017.8: 271. Doi.10.1007
4. Young Kyeong Seo, Chae Hun Lee, Hyun- Kyung Lee, et al. Difference between patients with tuberculous destroyed lung and chronic obstructive airway disease admitted to ICU. *Tuberc Respir Dis* 2011; 70 : 323-9
5. Consunji- Araneta R, Higgins R. Qing Gefei, Bouhasan Lanya. Destroyed lung in a child. *Pediatr Pulm* 2011; 46: 1247 – 50
6. Crespo GM, Martinez AF, González CFJ. Destroyed lung complicated with empyema. *Imaging Med* 2016; 8: 113 – 5
7. Blyth DF, Backels NJ, Sewsunker R, Soni MA. Pneumonectomy in children. *Eu J Cardio – thoracic Surgery* 2002; 22: 587 – 94
8. Eren S, Eren MN, Bala AE. Pneumonectomy in children for destroyed lung and the long term consequences. *J Thorac cardiovasc Surg* 2003, 126: 574-81
9. George MD. Radiologic features of Right destroyed lung syndrome with pathologic dextrocardia. *International J Trop Dis and health* 2014; 4: 437 – 43
10. Adefuye BO, Adefuye PO, Ogunkoya OJ. Right destroyed lung in a Nigerian woman with complicated Tuberculosis simulating Situs inversus. *Abstr Am J Respir Crit Care Med*. 2010; 181: 5456
11. Adebajo SA, Adebo OA, Osinowo O, Grillo IA. Management of TB destroyed lung. *J Natl Med Assoc*. 1981; 73: 39 – 42
12. Hyae Young Kim, Koun-Sik Song, Jin M Goo, Jin Seon Lee, Kyoung Soo Lee, Tae- Hwan Lim. Thoracic sequelae and complications of TB 2001. [https:// doi. Org/10.1148/radiographics.21.4.g01j106839](https://doi.org/10.1148/radiographics.21.4.g01j106839)
13. Lee RJJ, Chun JH, Chang EM, Shim JH. Clinical outcomes and prognostic factors in patients with Tuberculous destroyed lung. *The international journal of Tuberculosis and lung disease*. 2011, 15:246-250
14. Giubergia V, Alessandrini F, Barrias C, et al Risk factors for morbidities and mortality in children following Pneumonectomy. *Respirology*, 2017, 22, 187-191, doi. 10.1111/res./12867