

Malignant histiocytosis of lungs and chest wall: A case report of diagnostic conundrum and treatment challenges in a resource-poor setting

Jameel Ismail Ahmad,¹
Ismail Mohammed Inuwa,¹
Dalha Gwarzo Haliru,²
Imam Mohammed Ibrahim³

¹Division of Cardiothoracic Surgery, Surgery Department, ²Department of Hematology, ³Department of Histopathology, Bayero University Kano, Aminu Kano Teaching hospital, Kano, Nigeria

Abstract

Malignant histiocytosis is a rare condition with variable clinical presentation and prognosis. Its diagnosis requires high index of suspicion and further evaluation. Thus, it poses a diagnostic as well as management challenges especially in resource poor setting. The objective is to highlight the diagnosis and treatment challenges in the management of malignant histiocytosis so that physicians can diagnose it early and initiate appropriate treatment. Our patient is a 35-year-old man who presented with chest wall mass, dyspnoea and right cervical lymphadenopathy. He was initially being evaluated for lymphoma. Biopsy of the lymph nodes was done twice in different hospitals and that of the chest wall mass done once. Histological diagnosis was arrived at with the aid of immunohistochemistry three months after his first presentation to the hospital. The patient was then commenced on chemotherapy and showed remarkable improvement on the short-term basis. Malignant histiocytosis is a rare disease laden with management challenges. Despite that, its diagnosis and treatment can be achieved even in resource poor setting with high index of suspicion, team work and good laboratory support.

Introduction

Malignant histiocytosis of the lungs and chest wall is a rare condition with variable clinical presentation and prognosis. The diagnosis requires high index of suspicion and further evaluation and it poses a diagnostic as well as management challenges especially in resource poor setting.¹

Case Report

We present a 35-year-old man referred to our centre from a tertiary hospital located about 160 km away with a 10 months history of slowly growing anterior chest wall mass followed 3 months later by dyspnoea which was initially on exertion and later at rest (dyspnoea score of 5). There was associated orthopnoea, dry cough, low-grade fever, weight loss and dysphagia. The chest wall mass later spontaneously ruptured and started discharging serous fluid. A right sided neck swelling then appeared about 2 months to presentation. Left tube thoracostomy was done for the patient 3 months earlier which drained serous fluid. He had significant history of second-hand smoking and a positive family history of breast cancer in his half-sister.

On examination he was chronically ill-looking with a body mass index of 17.1 kg/m², Karnofsky performance status scale of 20% and in marked respiratory distress but was haemodynamically stable. He had multiple, matted, hard and non-tender right supraclavicular lymphadenopathy and bilateral medial group of axillary lymph nodes. There was an anterior chest wall mass across the sternum about 30×20 cm with soft and hard components and attached to the skin and the underlying bones. There were dull percussion notes and decreased air entry over the middle and lower chest zones which was more on the left. The liver and spleen were not enlarged. Lymphoma, chest wall tumour and tuberculosis were entertained as differential diagnoses.

Sputum Acid-Fast bacilli (AFB) and retroviral screening were both negative and full blood count, clotting profile, urea, electrolytes and creatinine and liver function were normal. Chest X-ray showed bilateral non-patchy opacities more on the left side (Figure 1) and a chest CT Scan showed isodensity occupying most of the left lung field and a chest wall mass involving the sternum and the anterior ribs with intra-thoracic extension (Figure 2). Test aspiration revealed free flowing serous pleural fluid bilaterally.

A biopsy of the right cervical lymph node at the referring hospital revealed adipose tissue, fibromuscular tissue and thickened vascular channels with areas showing lymphocytic infiltrates and histiocytes. A suspicion of malignancy was high and immunohistochemistry was advised. A repeat cervical lymph node biopsy at our centre was also not conclusive and a trucut biopsy of the chest wall mass was done to examine the two samples. The result showed infiltrating clusters and sheets of large ovoid cells with vesicular hyperchromatic nuclei and abundant eosinophilic cytoplasm disposed within a fibrocollagenous tissue containing moderate infiltrates of neutrophils, eosinophils, lymphocytes and mast cells (Figure 3) and Immunohistochemistry showed S₁₀₀ positivity (Figure 4). Thus, a histological diagnosis of malignant histiocytosis was then made.

Correspondence: Jameel Ismail Ahmad, Division of Cardiothoracic Surgery, Surgery Department, Bayero University Kano/Aminu Kano Teaching hospital, PMB 3452, Kano, Nigeria.
E-mail: iajameel@yahoo.com

Key words: Malignant histiocytosis, diagnosis, treatment, challenges, immunohistochemistry.

Contributions: the authors contributed equally.

Conflict of interest: the authors declare no potential conflict of interest.

Funding: none.

Received for publication: 30 July 2018.

Accepted for publication: 5 October 2018.

This work is licensed under a Creative Commons Attribution NonCommercial 4.0 License (CC BY-NC 4.0).

©Copyright J.I. Ahmad et al., 2018

Licensee PAGEPress, Italy

Pyramid Journal of Medicine 2018; 1:9

doi:10.4081/pjm.2018.9

Bone marrow, liver and Splenic involvements were excluded with bone marrow aspiration and abdominal ultrasound scan. We then made the diagnosis of multi-systemic Langerhan's cell malignant histiocytosis of the lung, chest wall and the lymphatic system.

Bilateral tube thoracostomy was done to drain the pleural effusions. The patient was prepared for chemotherapy which is the standard treatment and he was commenced on Vinblastine and prednisolone regimen as recommended by the Histiocyte Society evaluation and treatment guidelines 2009 (Vinblastine 6 mg/m² = 10 mg weekly and Prednisolone 40 mg/m² = 60 mg daily). Adjunctive treatments included antacids, Allupurinol, analgesics and antibiotics. He successfully completed the 7-weeks first course of the induction treatment and made remarkable improvement evidenced by regression of the chest wall mass and the right supraclavicular lymph nodes (Figure 5), improved dyspnoea score (from 5 to 1) and Karnofsky performance status scale (from 20% to 80%).

Bilateral tube thoracostomy was done to drain the pleural effusions. The patient was prepared for chemotherapy which is the standard treatment and he was commenced on Vinblastine and prednisolone regimen as recommended by the Histiocyte Society evaluation and treatment guidelines 2009 (Vinblastine 6 mg/m² = 10 mg weekly and Prednisolone 40 mg/m² = 60 mg daily). Adjunctive treatments included antacids, Allupurinol, analgesics and antibiotics. He successfully completed the 7-weeks first course of the induction treatment and made remarkable improvement evidenced by regression of the chest wall mass and the right supraclavicular lymph nodes (Figure 5), improved dyspnoea score (from 5 to 1) and Karnofsky performance status scale (from 20% to 80%).

The 7-weeks second course of the induction treatment was commenced but the patient became less compliant as the support he receives from sponsoring relations dwindled and the course was also interrupted by episodes of anaemia, leucopenia and thrombocytopenia, generalized body rashes and ulceration of the chest wall mass. He then absconded but we traced him after 6 weeks and convinced him and the relations on the need to return for evaluation and commencement of maintenance treatment.

1. Systemic chemotherapy is the main stay of treatment of LCH but radiotherapy and hormonal therapy may also be used. Surgery has limited role. The indications for systemic therapy include SS-LCH with

“CNS-risk” lesions, SS-LCH with multifocal bone lesions (MFB), SS-LCH with “special site” lesions and MS-LCH with/without involvement of “risk organs”. Treatment duration of 12 months is advocated over 6

Discussion

Langerhan’s cell histiocytosis is a rare condition especially in adults. The International Histiocyte registry reported 274 cases from 13 countries in 18 months.² Pulmonary LCH is even rarer with a prevalence of 0.07-0.27/1,000,000 population.³ It is commoner among 20-40 years old.

The specific aetiology of pulmonary LCH is unknown but cigarette smoking is highly associated with it in about 50-90% of cases.^{2,4}

The clinical presentation is variable from being asymptomatic to dyspnoea, cough, chest pain, soft tissue, bone swelling, weight loss, night sweats and fever. Spontaneous pneumothorax is reported in 10-20% of patients.⁵⁻⁸ Increased thirst and polyuria suggest hypothalamic and/or pituitary involvement.

Cytological and histological evaluation from Transthoracictrucut biopsy, bronchoalveolar lavageor Video assisted thoracic surgery biopsy is diagnostic. Presence of Birbeck granules and immunohistochemical demonstration of Langerin (CD 207) and CD1a. S₁₀₀ is an important marker although it can be found in macrophages and neuroendocrine cells.^{4,9}

There are different classifications for LCH. However, the two commonly use are: World Health Organisation (WHO) classification and Histiocyte Society classification and Clinical classification which classified it into Single System LCH (SS-LCH) and Multi-System LCH (MS-LCH) as in Table

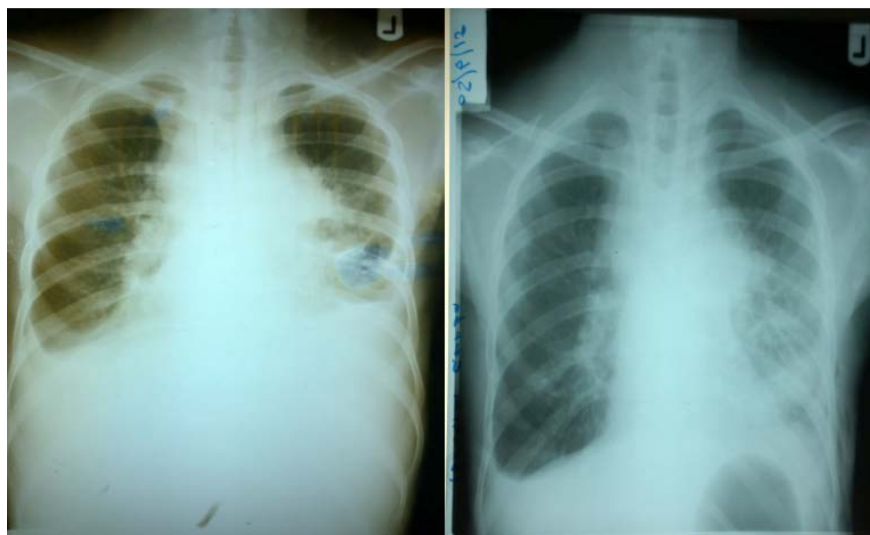


Figure 1. Chest X-ray for the patient with pulmonary malignant histiocytosis.

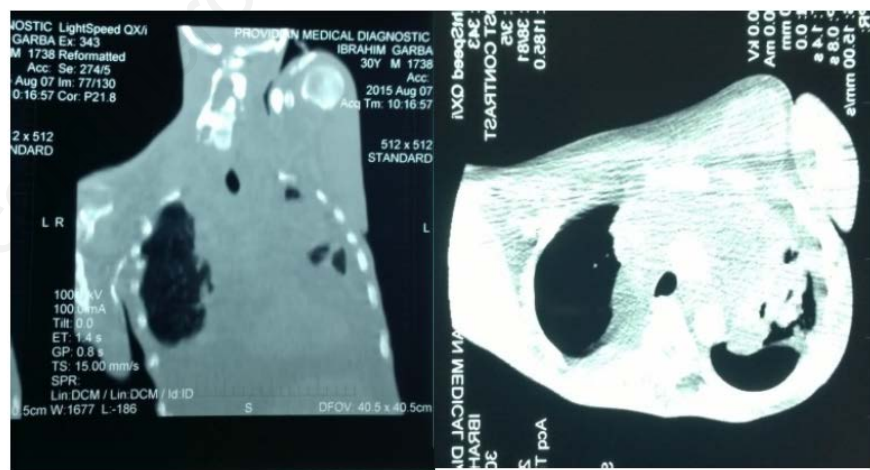


Figure 2. Chest computed tomography scan for the patient with pulmonary malignant histiocytosis.

Table 1. Two main classifications for Langerhans cell histiocytosis.

Single System LCH (SS-LCH)	Multisystem LCH (MS-LCH)
One organ/system involved (uni- or multifocal).	Two or more organs/systems involved.
Bone: unifocal (single bone) or multifocal (>1 bone).	With or without involvement of “Risk Organs”
Skin. Lymph node (not the draining lymph node of another LCH lesion).	
Lungs.	
Hypothalamic-pituitary/central nervous system.	
Other (e.g. thyroid, thymus)	

months. A combination of prednisone (PRED) and vinblastine (VBL) has been proven to be effective treatment with minimal toxicity.

MS-LCH patients like ours can have a variable clinical course. Those with or without risk involvement who respond to standard initial therapy have an excellent chance of long-term survival while non-responders have an unfavourable prognosis.

The treatment strategies for pulmonary LCH include cessation of smoking/exposure, systemic chemotherapy, systemic steroid therapy and Lung transplantation (in severe respiratory failure or major pul-

monary hypertension). Pneumocystis Jirovecii prophylaxis, analgesics, antibiotics are some of the adjunct treatments.

Conclusions

Langerhans cell histiocytosis is a rare disease with the malignant being rarer whose characteristics are not clearly defined in adults. Pulmonary langerhans cell histiocytosis is an entity associated with smoking. There are diagnostic and treatment challenges in the resource poor settings.

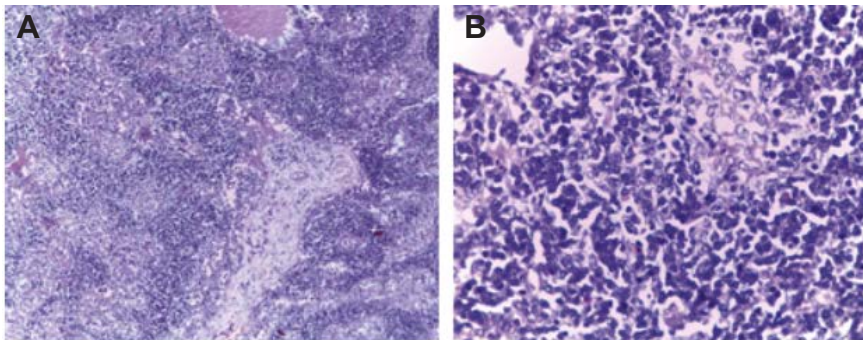


Figure 3. A) Section shows infiltrating nests of large ovoid-shaped Histiocytes disposed within a fibrocollagenous tissue containing moderate infiltrates of neutrophils, eosinophils, lymphocytes and mast cells. B) Section shows infiltrating nests and sheets of malignant Histiocytes with vesicular hyperchromatic nuclei, occasional prominent nucleoli and abundant eosinophilic cytoplasm.

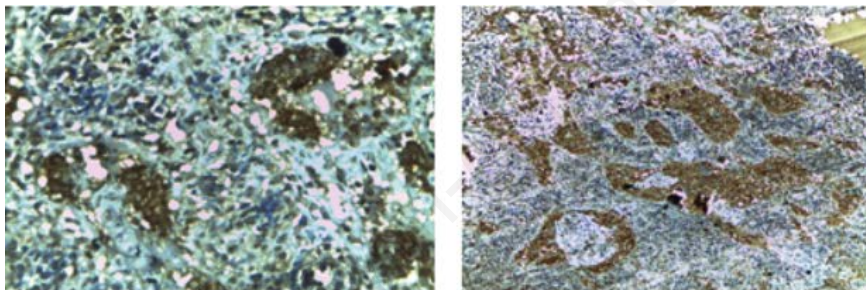


Figure 4. Immunohistochemistry section demonstrating S-100 positivity.

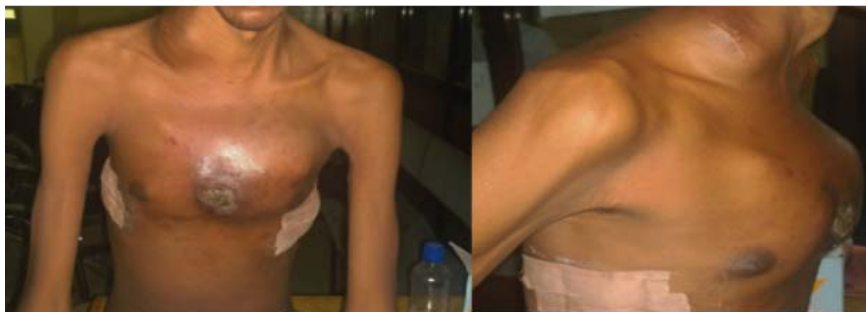

Figure 5. Decrease in size of chest wall mass following chemotherapy.

References

1. Histiocyte society. Langerhans cell histiocytosis: Histiocyte society evaluation and treatment guidelines. 2009. Available from: <http://www.histiocyte-society.org>.
2. Arico M, Girchikofsky M, Genereau T, et al. Langerhans cell histiocytosis in adults: report from the international registry of the histiocyte society. *Eur J Cancer* 2003;39:2341-8.
3. Watanabe R, Tatsumi K, Hashimoto S, et al. Clinico-pathological features of pulmonary Histiocytosis X. *Intern Med* 2001;40:998-1003.
4. Girchikofsky M, Arico M, Castillo D, et al. Management of adult patients with Langerhans cell histiocytosis: Recommendations from an expert panel on behalf of Euro-Histio-Net. *Orphanate J Rare Dis* 2013;8:72.
5. Tazi A. Adult pulmonary Langerhans cell histiocytosis. *Eur Resp J* 2006;27:1272-85.
6. Adam Z, Rehak Z, Koukalova R, et al. Pulmonary langerhans cell histiocytosis-evaluation of the disease activity and treatment response using PET-CT (SUV max) Pulmo/SUV max Hepar index);Description of own experience and literature review. *VnitrLek* 2010;56:1228-5.
7. Bianchi M, Cataldi M. Pneumothorax secondary to pulmonary histiocytosis X. *Minerva Chir* 1999;54:531-6.
8. Kim CK, Park CB, Jun U, Seo EJ. Pulmonary langerhans cell histiocytosis presented with recurrent pneumothorax. *Interac Cardiovasc Thorac Surg* 2006;5:512-3.
9. Adam Z, Pour L, Krejci M, et al. Langerhans cell histiocytosis in adult patients: A disease with many faces: experience of a centre and an overview of the disease symptoms. *Vnitr Lek* 2008;54:1063-80.